

Editor-in-Chief :  
Atul Goel  
(INDIA)

Open Access  
HTML Format

For entire Editorial Board visit : <http://www.jcvjs.com/editorialboard.asp>

## Original Article

# Cervical disc hernia operations through posterior laminoforaminotomy

Coskun Yolas, Nuriye Guzin Ozdemir<sup>1</sup>, Hilmi Onder Okay, Ayhan Kanat<sup>2</sup>, Mehmet Senol, Ibrahim Burak Atci<sup>1</sup>, Hakan Yilmaz<sup>3</sup>, Mustafa Kemal Coban, Mehmet Onur Yuksel, Umit Kahraman

Department of Neurosurgery, Erzurum Regional Training and Research Hospital, Erzurum, <sup>1</sup>Department of Neurosurgery, Istanbul Training and Research Hospital, Istanbul, <sup>2</sup>Department of Neurosurgery, Recep Tayyip Erdogan University, Rize, <sup>3</sup>Department of Neurosurgery, Duzce Ataturk State Hospital, Duzce, Turkey

Corresponding author: Dr. Hakan Yilmaz, Department of Neurosurgery, Duzce Ataturk State Hospital, Duzce, Turkey. E-mail: [dr\\_hakanyilmaz@hotmail.com](mailto:dr_hakanyilmaz@hotmail.com)

Journal of Craniovertebral Junction and Spine 2016, 7:20

## Abstract

**Objective:** The most common used technique for posterolateral cervical disc herniations is anterior approach. However, posterior cervical laminoforaminotomy can provide excellent results in appropriately selected patients with foraminal stenosis in either soft disc prolapse or cervical spondylosis. The purpose of this study was to present the clinical outcomes following posterior laminoforaminotomy in patients with radiculopathy. **Materials and Methods:** We retrospectively evaluated 35 patients diagnosed with posterolateral cervical disc herniation and cervical spondylosis with foraminal stenosis causing radiculopathy operated by the posterior cervical keyhole laminoforaminotomy between the years 2010 and 2015. **Results:** The file records and the radiographic images of the 35 patients were assessed retrospectively. The mean age was 46.4 years (range: 34-66 years). Of the patients, 19 were males and 16 were females. In all of the patients, the neurologic deficit observed was radiculopathy. The posterolaterally localized disc herniations and the osteophytic structures were on the left side in 18 cases and on the right in 17 cases. In 10 of the patients, the disc level was at C5-6, in 18 at C6-7, in 2 at C3-4, in 2 at C4-5, in 1 at C7-T1, in 1 patient at both C5-6 and C6-7, and in 1 at both C4-5 and C5-6. In 14 of these 35 patients, both osteophytic structures and protruded disc herniation were present. Intervertebral foramen stenosis was present in all of the patients with osteophytes. Postoperatively, in 31 patients the complaints were relieved completely and four patients had complaints of neck pain and paresthesia radiating to the arm (the success of operation was 88.5%). On control examinations, there was no finding of instability or cervical kyphosis. **Conclusion:** Posterior cervical laminoforaminotomy is an alternative appropriate choice in both cervical soft disc herniations and cervical stenosis.

**Key words:** Cervical disc herniation, foraminal stenosis, posterior laminoforaminotomy

Access this article online	
Quick Response Code:	Website: <a href="http://www.jcvjs.com">www.jcvjs.com</a>
	DOI: 10.4103/0974-8237.181854

This is an open access article distributed under the terms of the Creative Commons Attribution-NonCommercial-ShareAlike 3.0 License, which allows others to remix, tweak, and build upon the work non-commercially, as long as the author is credited and the new creations are licensed under the identical terms.

**For reprints contact:** [reprints@medknow.com](mailto:reprints@medknow.com)

**How to cite this article:** Yolas C, Ozdemir NG, Okay HO, Kanat A, Senol M, Atci IB, *et al.* Cervical disc hernia operations through posterior laminoforaminotomy. *J Craniovert Jun Spine* 2016;7:91-5.

## INTRODUCTION

Cervical disc herniation and cervical spondylosis are frequently encountered progressive diseases. The herniated material and the osteophytes compress the spinal cord and the nerve roots, resulting in clinical symptoms.<sup>[1]</sup> From the year 1958, when Smith and Robinson made the first description, until today a high number of cervical disc hernia operations utilizing the anterior method with or without fusion have been performed. Cervical disc operation with posterior cervical laminoforaminotomy was first described by Scoville in the year 1946.<sup>[2]</sup> This method was used as a trustworthy and effective treatment for suitable cases.<sup>[3-5]</sup> Surgical intervention is necessary in patients with cervical disc hernia and spondylosis suffering from severe pain and neurological deficits. While surgical interventions can be performed through an anterior approach, a posterior approach in appropriate cases may have excellent results.

The anterior approach is mandatory for patients with midline or paramedian localized cervical disc herniation and osteophytes. However, for patients with posterolaterally located disc herniations and osteophytic structures, a posterior approach may be more favorable than an anterior approach. The primary disadvantage of the anterior cervical approach is the proximity of the neurovascular structures and the esophagus to the operation area; traumatization of these structures is possible during the operation.

However, in the posterior cervical approach these structures remain at a distance from the surgical field. Furthermore, the posterior cervical approach is very easy compared to the anterior approach. The limitation of this approach is that the intervention can only be performed on patients with posterolaterally located cervical disc herniation, osteophytes, and intervertebral foraminal stenoses.<sup>[6,7]</sup> The other advantages of this technique are the short duration of operation in the posterior cervical laminoforaminotomy, preservation of the mobility of the operated segments, accessibility to one or multiple segments with bilateral foraminotomies, and when necessary, allowing laminectomy and laminoplasty as well as canal stenoses at the same session. Economically, due to the fact that cage, prosthesis, and graft are not used in the posterior approach, they are cheaper than cervical disc operations through the anterior approach.<sup>[8,9]</sup> However, with all of its advantages, posterior cervical disc hernia operations have not been much preferred lately.

## MATERIALS AND METHODS

Between the years 2010 and 2015, posterior keyhole laminofroaminotomy was performed in the Erzurum Regional Training and Research Hospital Neurosurgery Clinic on 35 patients with cervical radiculopathy. Postoperative data of patients with a diagnosis of cervical disc herniation and cervical spondylotic radiculopathy were retrospectively reviewed. The cervical magnetic resonance imagings (MRIs) and the cervical computed tomographies (CTs) of these patients were retrospectively assessed.

The patients were placed prone in reverse trendelenburg position with the head positioned in a Mayfield fixator, maintaining the neck in a neutral position. The paravertebral muscles were separated subperiosteally and retracted to the level of facets. The level was determined using the C-armed fluoroscopy. Under microscopy, minimal laminoforaminotomy was performed using the 2 mm Kerrison rongeur (Intepro) or the drill with the high speed diamond tip. The protruded or sequestered disc structures were observed to be located at the anterior of the junction of the dural sac and the root. With the help of a micro nerve hook (Intepro), the root was elevated by entering the shoulder or the axilla and the disc fragments were extracted. The osteophytic structures were slightly separated from the roots and excised with a curette (Intepro). The foramina were decompressed until both proximal and distal pedicles were confirmed and a probe was inserted into the foramen easily.

The protruded discs were extracted through incision of the dorsal longitudinal ligament following minimal retraction of the root. However, the disc space was not entered at any time during the procedure. Foraminotomy was performed until the root was totally decompressed. During this procedure, the medial part of the facet was excised to a certain extent and no deterioration of the facet integrity that could result in instability was allowed. Disturbing bleedings from venous structures during the operation were easily coagulated using hemostatic agents or bipolar cauterization.

In the postoperative period, analgesic and anti-inflammatory drugs were administered to the patients for 1 week and the patients wore soft cervical collars for 2 weeks. The duration of the hospital stay was 2 days in the postoperative period. The patients' preoperative and postoperative degrees of pain at 6th month of follow-up were questioned. The Numeric Pain Scale (NPS) was used for this evaluation grading from 0 (no pain) to 10 (intolerable pain).

The obtained data were evaluated by using the Statistical Package for the Social Sciences (SPSS) 15.0 software (SPSS, Inc, Chicago, IL, USA) for taking statistics. Descriptive statistical methods were utilized while assessing the data. Two groups were compared by using *t*-test in independent groups.  $P < 0.05$  was taken as the statistical level of significance.

## RESULTS

The file records and radiographic images of the 35 patients were assessed retrospectively. The patients were aged 34-66 years. Nineteen patients were males and 16 were females. The posterolaterally localized disc herniations and the osteophytic structures were on the left side in 18 cases, and on the right in 17 cases. In 10 of the patients, the disc level was at C5-6, in 18 of the patients at C6-7, in 2 patients at C3-4, in 2 patients at C4-5, in 1 patient at C7-T1, in 1 patient at both C5-6 and C6-7, and in 1 patient at both C4-5 and C5-6 [Table 1, Figure 1].

In 14 of these 35 patients, both osteophytic structures and protruded disc herniation were present. Intervertebral foramen

**Table 1: Herniated cervical disc levels and number of patients**

Disc level	Number of the patients
C6-7	18
C5-6	10
C4-5	2
C3-4	2
C7-T1	1
C5-6, C6-7	1
C4-5, C5-6	1

stenosis was observed in the patients with osteophytes. Cervical radiographies, cervical MRIs, and in those with osteophytic structures, cervical CTs were additionally performed on all cases in the preoperative period [Figure 2a and b].

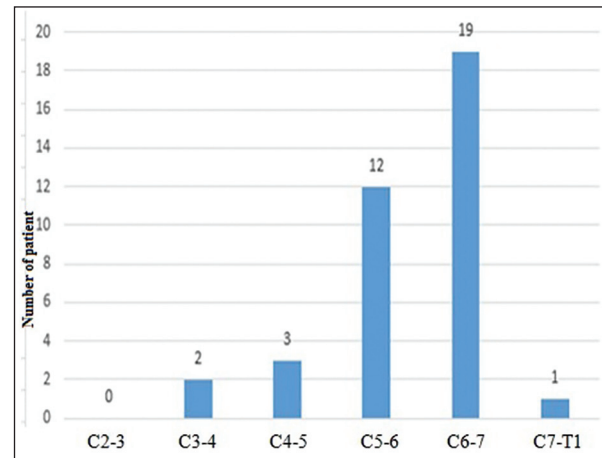
In the postoperative period, at the 3rd month cervical x-rays and MRIs were performed on the patients [Figures 3a and b]. While 31 of this 35-patient group had stated that their complaints had completely subsided, 4 patients had complaints of neck pain and paresthesia radiating to the arm (the success of operation was 88.5%). In one patient, the vertigo that had developed in the early postoperative period was observed to have significantly regressed at the 3rd month following conservative treatment. In another patient, on controls a recurrence of a medially localized cervical disc hernia was observed. An operation was recommended to the patient. However, the patient did not approve of the operation, and he was recommended medical and physical therapies.

On the control examinations, there were no findings of instability or cervical kyphosis. However, varying degrees of straightening of the cervical lordosis were determined on the lateral cervical radiographies of nine patients. This finding was more marked in patients describing pain in the neck.

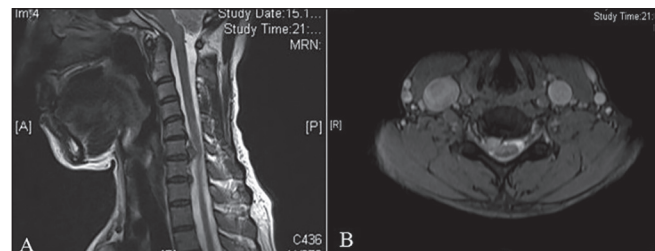
For further evaluation of the patients' outcomes during controls in the outpatient clinic over the 6-month follow-up period, the patients were divided into two groups. The first group comprised a group of 20 individuals who had undergone the operation through an anterior approach and at a single level. The second group comprised the 35 patients who had cervical laminoforaminotomy approach at a single level. The patients' preoperative and current degrees of pain were questioned. The NPS was used for this evaluation grading from 0 (no pain) to 10 (intolerable pain). According to this scale, the preoperative pain degree was 6.5 on an average in both the groups. While the average of the pain degree was 1.75 in the first group at the time of the questioning, this value in the second group was 1.7. Therefore, no significant difference was observed between the groups regarding the degree of pain ( $P > 0.05$ ).

## DISCUSSION

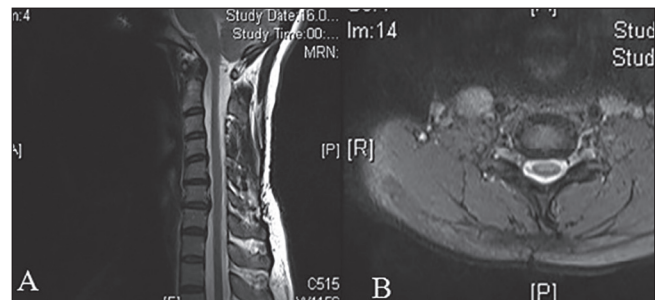Cervical disc hernias and cervical spondylosis causing neurological deficits and severe pain is a clinical picture that is



**Figure 1: Herniated cervical disc levels and number of patients**



**Figure 2: (a and b) Cervical sagittal T2-weighted MRI demonstrating cervical disc herniation at C6-7 level and axial image showing soft disc herniation on the right side**



**Figure 3: (a and b) Cervical sagittal and axial T2-weighted MRI demonstrating that soft disc herniation was removed and the lordosis was protected**

observed very frequently. The diagnosis can be easily made with cervical radiographies, cervical MRIs, and cervical CTs. Surgical treatment is required in cases not responding to medical treatment.<sup>[10]</sup>

Anterior cervical discectomy is the most frequently utilized approach in the treatment of cervical disc hernias. However, possible complications in this approach are quite frequently encountered. Complications that may develop during the operation include esophagus perforations, vessel-nerve injuries, cerebral ischemias secondary to long-lasting excessive retraction of the carotid artery, lesion of the sympathetic plexus in the carotid artery wall, vocal cord paralysis secondary to recurrent laryngeal nerve traumas, and injuries to the medulla spinalis, dura mater, and the roots.<sup>[11-16]</sup> Postoperative complications

are dislocations of the cage, neighboring segment syndrome, and infections. These types of complications are not observed in operations performed through posterior cervical laminoforaminotomy. However, complications such as neck pain, root injury, and cerebrospinal fluid leakage secondary to tear of the dura mater, epidural hematoma, radiculitis, wound infection, and very rarely, vertebral artery injury may be observed.<sup>[17-20]</sup> In our series, skin infection developed in only one patient, and in this case the infection healed with antibiotic treatment.

Another disadvantage of the posterior approach is the limited indication of the technique; only patients with posterolaterally localized cervical disc hernias, cervical spondylosis, and root compressions secondary to intervertebral foramen stenosis are operated using the posterior cervical laminoforaminotomy.<sup>[21]</sup> Furthermore, the field of view in posterior laminoforaminotomy is partially restricted. Resection of osteophytic structures may sometimes be difficult through this approach. Neck pain secondary to retraction of cervical muscle may also develop in the postoperative period. In order to prevent this pain, there are recommendations to loosen the retractors every 20 min during the operation to relieve the paravertebral muscles or to perform endoscopic intervention through the tubular method.<sup>[4,20]</sup>

Posterior cervical laminoforaminotomies may be performed in a sitting or prone position. We operated all of our patients in the prone position. Cervical disc operations performed through the posterior laminoforaminotomy method are simpler and more trustworthy than anterior cervical hernia operations and also cheaper. This is because the duration of stay in the hospital after these operations is shorter and the infection rates are much lower. Furthermore, intercorporeal prosthesis, cage, or graft are not used and the patients return to work at an earlier stage postoperatively.<sup>[4,8]</sup> In the postoperative follow-up period, the evaluation of the pain scale was graded according to NPS after an interview with the patients who had undergone the operations through anterior and cervical laminoforaminotomy approaches. There was no significant difference between the average of postoperative pain of the both the groups.

It has been emphasized that in the treatment of patients with severe radiculopathy, operations performed through the posterior laminoforaminotomy approach are more effective than cervical disc operations performed through the anterior approach.<sup>[21,22]</sup> In a series presented by Lubelski *et al.*, it was reported that the majority of the patients with posterolaterally located cervical disc herniation were males and of an old age.<sup>[23]</sup> The mean age of the patients in our group was 46.4 years and the majority of the patients were male (19 patients). In the series of 35 patients that we have presented, the localization of the posterolaterally located disc protrusion and osteophytic structures was on the left side in 18 cases, and the localization was on the right side in 17 cases.

The disc spaces in which cervical disc herniations are observed most frequently have been emphasized to be, in decreasing order, C6-7 and C5-6. The same finding was observed in our 35-patient group. Due to the shortness of the C5 root, extraction

of the disc protrusion at the C4-5 space is more difficult than from other disc spaces and for this reason, it has been stated that a wider laminoforaminotomy is required for this disc space.<sup>[22]</sup> Some authors have emphasized that reoperations may sometimes be required following posterior cervical laminoforaminotomy. In a presented series, the rate of reoperation has been reported to be 9.9%. This type of reoperations has been emphasized to have generally occurred due to incorrect diagnosis, wrong side, and wrong level.<sup>[23,24]</sup> Only in one patient reoperation was required; however, the patient did not approve of it and physical therapy with medication was recommended. However, the short duration of follow-up period may not allow evaluation of the real percentage of the patients requiring reoperation.

## CONCLUSION

Approximately 1/3rd of the patients with cervical disc hernia and cervical spondylosis may be operated through the posterior cervical laminoforaminotomy approach. Operations performed for posterolaterally localized disc herniation, cervical spondylosis, and intervertebral foramen stenosis through the posterior cervical laminoforaminotomy approach are more trustworthy than those performed through the anterior approach. The preoperative and postoperative complications in operations performed through the posterior laminoforaminotomy approach are much lower and less significant than in cervical disc hernia and cervical spondylosis operations performed through the anterior approach. The mobilization of the affected segment in cervical disc operations performed through posterior cervical laminoforaminotomy is preserved. Due to the fact that these operations are performed through the posterior approach, no prosthesis, cage, or graft is used and furthermore, due to the low rate of complications the operation costs are lower.

## Financial support and sponsorship

Nil.

## Conflicts of interest

There are no conflicts of interest.

## REFERENCES

1. Bydon M, Mathios D, Macki M, de la Garza-Ramos R, Sciubba DM, Witham TF, *et al.* Long-term patient outcomes after posterior cervical foraminotomy: An analysis of 151 cases. *J Neurosurg Spine* 2014;21:727-31.
2. Epstein NE. A review of laminoforaminotomy for the management of lateral and foraminal cervical disc herniations or spurs. *Surg Neurol* 2002;57:226-33.
3. Church EW, Halpern CH, Faight RW, Balmuri U, Attiah MA, Hayden S, *et al.* Cervical laminoforaminotomy for radiculopathy: Symptomatic and functional outcomes in a large cohort with long-term follow-up. *Surg Neurol Int* 2014;30(Suppl 15):S536-43.
4. Grieve JP, Kitchen ND, Moore AJ, Marsh HT. Results of posterior cervical foraminotomy for treatment of cervical spondylitic radiculopathy. *Br J Neurosurg* 2000;14:40-3.
5. Zeidman SM, Ducker TB. Posterior cervical laminoforaminotomy for radiculopathy: Review of 172 cases. *Neurosurgery* 1993;33:356-62.
6. Caglar YS, Bozkurt M, Kahilogullari G, Tuna H, Bakir A, Torun F, *et al.* Keyhole approach for posterior cervical discectomy: Experience on 84 patients. *Minim Invasive Neurosurg* 2007;50:7-11.

7. Parker WD. Cervical laminoforaminotomy. *J Neurosurg* 2002;96(Suppl):254-5.
8. Alvin MD, Lubelski D, Abdullah KG, Whitmore RG, Benzel EC, Mroz TE. Cost utility analysis of anterior cervical discectomy and fusion with plating (ACDFP) versus posterior cervical foraminotomy (PCF) for Patients with single-level cervical radiculopathy at 1-year follow-up. *J Spinal Disord Tech* 2014. [Epub ahead of print].
9. Mansfield HE, Canar WJ, Gerard CS, O'Toole JE. Single-level anterior cervical discectomy and fusion versus minimally invasive posterior cervical foraminotomy for patients with cervical radiculopathy: A cost analysis. *Neurosurg Focus* 2014;37:E9.
10. Wang MY, Green BA. Laminoplasty for the treatment of failed anterior cervical spine surgery. *Neurosurg Focus* 2003;15:15-E7.
11. Cho TG, Kim YB, Park SW. Long term effect on adjacent segment motion after posterior cervical foraminotomy. *Korean J Spine* 2014;11:1-6.
12. Choi JH, Kim JS, Lee SH. Cervical spinal epidural hematoma following cervical posterior laminoforaminotomy. *J Korean Neurosurg Soc* 2013;53:125-8.
13. Eseoğlu M, Yılmaz I, Karalar M, Aydın MD, Kayaci S, Gundogdu C, et al. The role of sympathectomy on the regulation of basilar artery volume changes in stenocclusive carotid artery modeling after bilateral common carotid artery ligation: An animal model. *Acta Neurochir (Wien)* 2014;156:963-9.
14. Kim CH, Shin KH, Chung CK, Park SB, Kim JH. Changes in cervical sagittal alignment after single-level posterior percutaneous endoscopic cervical discectomy. *Global Spine J* 2015;5:31-8.
15. Lidar Z, Salame K. Minimally invasive posterior cervical discectomy for cervical radiculopathy: Technique and clinical results. *J Spinal Disord Tech* 2011;24:521-4.
16. Winder MJ, Thomas KC. Minimally invasive versus open approach for cervical laminoforaminotomy. *Can J Neurol Sci* 2011;38:262-7.
17. Dohrmann GJ, Hsieh JC. Long-term results of anterior versus posterior operations for herniated cervical discs: Analysis of 6000 patients. *Med Princ Pract* 2014;23:70-3.
18. Skovrlj B, Gologorsky Y, Haque R, Fessler RG, Qureshi SA. Complications, outcomes, and need for fusion after minimally invasive posterior cervical foraminotomy and microdiscectomy. *Spine J* 2014;14:2405-11.
19. Adamson TE. Microendoscopic posterior cervical laminoforaminotomy for unilateral radiculopathy: Results of a new technique in 100 cases. *J Neurosurg* 2001;95(Suppl):51-7.
20. Yang JS, Chu L, Chen L, Chen F, Ke ZY, Deng ZL. Anterior or posterior approach of full-endoscopic cervical discectomy for cervical intervertebral disc herniation? A comparative cohort study. *Spine (Phila Pa 1976)* 2014;39:1743-50.
21. Tomaras CR, Blacklock JB, Parker WD, Harper RL. Outpatient surgical treatment of cervical radiculopathy. *J Neurosurg* 1997;87:41-3.
22. Kang MS, Choi KC, Lee CD, Shin YH, Hur SM, Lee SH. Effective cervical decompression by the posterior cervical foraminotomy without discectomy. *J Spinal Disord Tech* 2014;27:271-6.
23. Lubelski D, Healy AT, Silverstein MP, Abdullah KG, Thompson NR, Riew KD, et al. Reoperation rates after anterior cervical discectomy and fusion versus posterior cervical foraminotomy: A propensity matched analysis. *Spine J* 2015;15:1277-83.
24. Wang TY, Lubelski D, Abdullah KG, Steinmetz MP, Benzel EC, Mroz TE. Rates of anterior cervical discectomy and fusion after initial posterior cervical foraminotomy. *Spine J* 2015;15:971-6.