

Clear Cell Atypical Fibroxantoma: A Rare Variant of Atypical Fibroxanthoma and Review of the Literature

RECEP BEDIR¹, SULE AGIRBAS², IBRAHIM SEHITOGLU³, CÜNEYT YURDAKUL⁴, ÖMER ELMAS⁵

ABSTRACT

Atypical fibroxanthoma (AFX) is a superficial variant of pleomorphic malignant fibrous histiocytoma. Clear cell atypical fibroxanthoma (CCAFXA) is a rare variant of atypical fibroxanthoma. A 74-year-old male patient presented with a rapidly growing nodule on the shoulder, which had appeared over a 5-months period. Lesion was excised by the plastic surgeon. Microscopic examination showed an ulcerated nodule composed of pleomorphic spindled and polygonal cells with clear or vacuolated cytoplasm. The neoplastic cells were stained positively with CD68 and CD10 and were stained negative with S-100, Melan A, muscle-specific actin, or pan-cytokeratin. Final diagnosis was clear cell atypical fibroxanthoma. CCAFXA should be differentiated from other clear-cell neoplasms of the skin. Best of our knowledge only 11 cases CCAFXA have been reported in published studies till date. Herein, we reported 12th case in literature of CCAFXA and review of the literature.

Keywords: Skin, Clear cell atypical fibroxanthoma, Immunohistochemistry, Differential diagnosis

CASE REPORT

A 74-year-old male patient with slightly elevated 2.5 cm nodule on the right shoulder which was completely excised. Microscopically, the epidermis showed acanthosis, hyperkeratosis, crust, and parakeratosis. In the dermis, just below the epithelium, solid tumour was found [Table/Fig-1]. Tumour consisted of polygonal or spindled cells with clear vacuolated cytoplasm, bizarre nuclei and marked nucleolus [Table/Fig-2]. Typical-atypical mitosis was increased in the tumour (mitotic rate 6/hpf). Tumour was negatively stained with Periodic Acid-Schiff (PAS) after diastase digest. Tumour was positively stained with vimentin, CD68 and CD10 [Table/Fig-3,4] but negatively stained with S-100, Melan A, HMB-45, muscle-specific actin (SMA), and pan-cytokeratin (pan-CK). These histopathologic and immunohistochemical features were consistent with diagnosis of CCAFX.

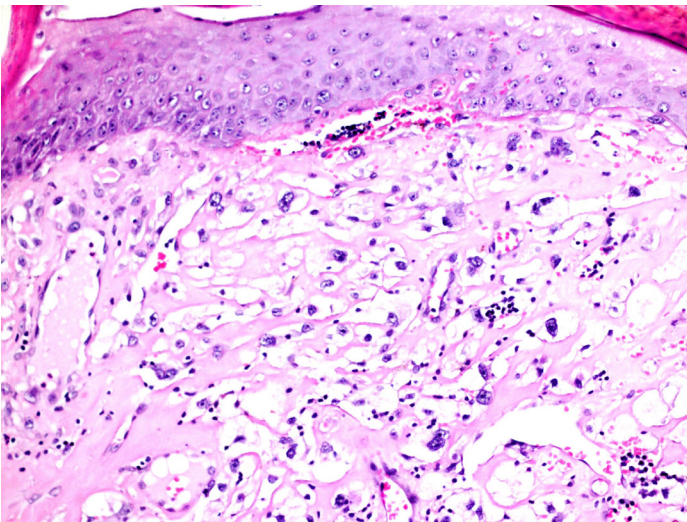
DISCUSSION

Atypical fibroxanthom (AFX) tends to be present in the head and neck region of elderly individuals. Clinically, it can be difficult to differentiate from other tumour without histopathological examination. Clear cell atypical fibroxanthoma (CCAFX) is rare variant of atypical fibroxanthoma AFX and must be distinguished from other clear cell lesions such as metastatic renal cell carcinoma, clear cell eccrine carcinoma, sebaceous carcinoma and clear cell sarcoma (malignant melanoma of soft part) and clear cell hidradenocarcinoma [1-3].

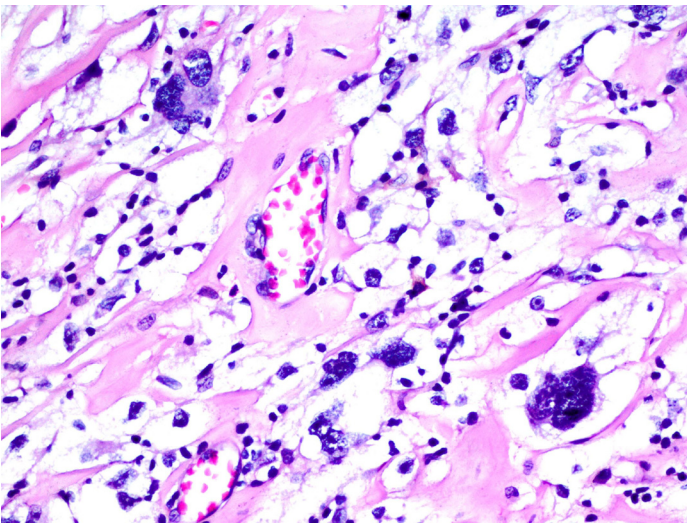
AFX is considered by the most authorities as a representation of a superficial variant of malignant fibrous histiocytoma. Microscopically, the tumour consisted of fascicles of spindle cells with bizarre nuclei and clear, vacuolated cytoplasm. Atypical multinucleated cells with Touton-like appearance and numerous atypical mitotic figures were present. PAS and PAS-D staining failed to demonstrate glycogen in tumour cells. The tumour cells were positively stained with vimentin, CD68, CD10 and CD99. Tumour cells were negatively stained with S-100 protein, pan-CK, EMA, SMA and MART-1 [1-5]. Smith-Zagone et al., [6] recently reported focal HMB-45 and MART-1 expression in the giant cells of AFX. Cai et al., [7] reported focal HMB-45 expression in a case with CCAFX. The reason for HMB-45 expression in this case of CCAFX is not clear. Our case was positively

stained with vimentin, CD68 and CD10, but negatively stained with S-100, Melan A, HMB-45, SMA and pan-CK. Reported the other cases in literature of histochemical and immunohistochemical staining profile of CCAFX are summarized in [Table/Fig-5].

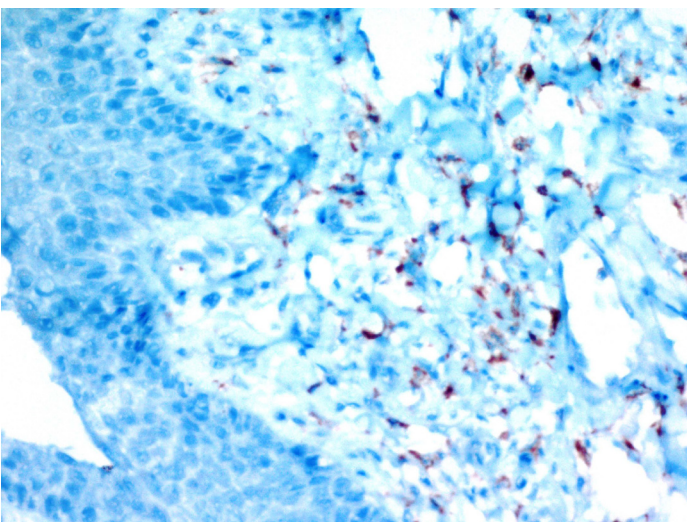
CCAFX should be differentiated from dermal neoplasms, either primary or metastatic, composed of clear cells such as squamous cell carcinoma, basal cell carcinoma, balloon cell malignant melanoma, tricholemmal carcinoma, adnexal carcinoma, renal cell carcinoma, clear cell sarcoma, cutaneous leiomyosarcoma, dermal pleomorphic liposarcoma, chordoma with cutaneous metastase or direct cutaneous extension, parachordoma and clear cell dermatofibroma [2-4]. The lack of S-100, Melan A and HMB-45 staining in CCAFX excludes clear cell (balloon cell) malignant melanoma, which is also a superficial, dermal tumour. Clear cell melanoma are not marked pleomorphism, bizarre multinucleation and numerous mitotic figures. Clear cell sarcoma usually affects younger individuals and is centred on deep structures. Tumour is composed of fascicles and islands of round or spindled clear cells with vesicular nuclei. These tumour contain cytoplasmic premelanosomes and are positive with S-100. Clear cell change in basal cell carcinoma and clear cell squamous cell carcinoma are typical of histopathological finding and stained positively with cytokeratin in contrast to CCAFX [3,4,8]. Clear-cell adnexal carcinoma is composed of a carcinoma with eccrine, apocrine, follicular, or sebaceous differentiation. Clear cell eccrine carcinoma is usually seen as a solitary nodule on an extremity showing lobular growth pattern with ovoid nuclei and peripheral rimming of basaloid cells without bizarre giant nuclei. In contrast to CCAFX tumour cells are positive with PAS and CK [3,4,9]. Cutaneous leiomyosarcoma shows fascicular arrangement, containing perinuclear vacuoles and PAS-positive cytoplasmic inclusions. In contrast to CCAFX tumour cells are positive with desmin and SMA [3,9]. Primary dermal pleomorphic liposarcoma is characterized by multivacuolated lipoblasts positively stained with S100 and calretinin, and negatively stained with CK and CD99 [3]. Chordomas and parachordomas are positively stained with S-100 and CK in contrast to CCAFX [4]. Dermatofibroma may contain clear cells and atypical cells may be seen. Clear-cell dermatofibroma is histologically characterized by thick collagen bundles interspersed



[Table/Fig-1]: There is hyperkeratotic epidermis under sheets of neoplastic cells in the papillary dermis (HE, x200)



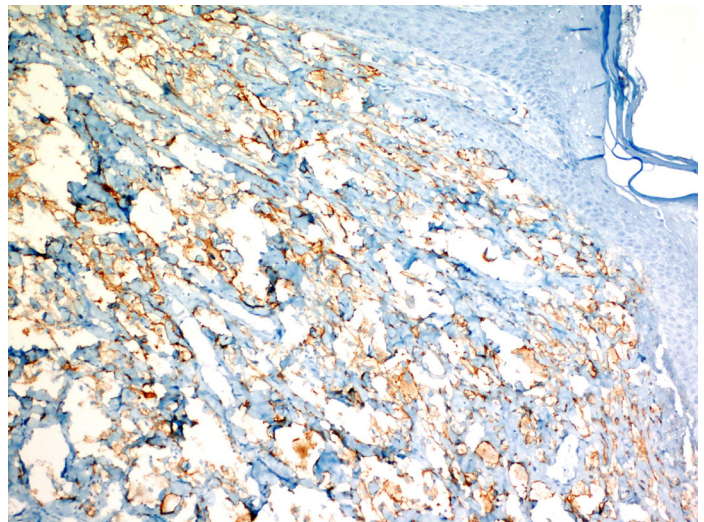
[Table/Fig-2]: Neoplastic cells present large hyperchromatic nucleus, prominent nucleoli, multinucleation and abundant clear or eosinophilic granular cytoplasm (HE, x200)



[Table/Fig-3]: Neoplastic cells was focal positivity with CD68 (x400)

with spindle cells at the periphery of the lesion, scant mitosis, no ulceration, and positive with Factor XIIIa, in contrast to CCAFV [3, 5, 9].

Metastatic clear cell carcinoma, in particular clear cell renal cell carcinoma, merits consideration in the differential diagnosis of CCAFV. While the presence of a tubulopapillary pattern favours renal cell carcinoma, such a pattern may be absent and these tumour may



[Table/Fig-4]: Neoplastic cells was diffuse positivity with CD10 (x100)

Case	PAS/ PAS-D	CD68	Vim	SMA	S-100	Melan A	CK	CD10
1 [8]	-	+	+	+	-	-	-	
2 [4]	-	+	-	-	-	-		
3 [4]	-	+	-	-	-	-		
4 [4]	-	+	-	-	-	-		
5 [5]	-	±	+	-	-	-	-	
6 [10]	-	-	+	+	-			
7 [10]	+	+	-					
8 [8]	-	-	-					
9 [7]	-	±	+	-	-	-	-	
10 [3]	-	+	+	-	-	-	-	-
11 [2]	-	+	+	-	-	-	-	+
12*	-	+	+	-	-	-	-	+

[Table/Fig-5]: Histochemical and immunohistochemical staining profile in reported cases of clear cell atypical fibroxantoma

Vim: Vimentin, SMA: smooth muscle actin, CK: cytokeratin +: present - : absent; PAS-D: PAS-Diastase

*Current case

Case	Age	Sex	Site	Size of lesion (mm)	History of growth	Atypical mitosis (10 hpf)	Atypical mitosis
1 [8]	67	M	Ear	10	2 weeks	14	+
2 [4]	88	M	Scalp	7 mm	n/k	4	+
3 [4]	77	M	Forearm	11 mm	n/k	32	+
4 [4]	78	M	Temple	8 mm	n/k	3	+
5 [5]	90	F	Cheek	25 mm	4 months	High	n/s
6 [10]	81	M	Temple	40 mm	3 months	n/s	+
7 [10]	73	M	Cheek	20 mm	6 months	n/s	+
8 [8]	87	M	Dorsum of hand	10 mm	2 months	Moderate	n/s
9 [7]	63	F	Forearm	n/s	n/k	High	n/s
10 [3]	86	F	Nose	14 mm	n/k	5	+
11 [2]	86	M	Right ear	10 mm	2 months	5	+
12*	74	M	Right shoulder	25 mm	5 months	6	+

[Table/Fig-6]: Clinical and pathological features of reported cases of clear cell atypical fibroxantoma

*Current case hpf: high power field n/k: detailed time of onset unknown n/s: not stated

closely mimicking CCAFV. Previous reports have emphasized the lack of a delicate arborizing vasculature in CCAFV to aid morphologic distinction between the tumour [4,8-10]. Metastatic clear cell carcinoma is positively stained with PAS, CD10 and cytokeratin but negatively stained CD68 and CD99 [8]. Recently, CD99, CD10 and c-kit (CD117) were described as sensitive antibodies of classic AFX. However, these antibodies have not been studied in most of the published CCAFV [2]. In our case showed positive staining with CD10. Therefore, CD10 expression is not useful in the distinguish CCAFV from metastatic clear cell carcinoma.

AFX occurs in elderly persons as a small nodule on the skin of the head and neck area. Sometimes, AFX can occur in different

locations as the present case. Only, Patterson et al., [9] reported atypical fibroxanthoma on the dorsum of the left hand. All of the other cases in the literature were localized on the head and neck. Reported the other cases in literature of clinical and pathological features of reported cases of CCAFX are summarized on [Table/Fig-6].

The risk factors for CCAFX are ultraviolet radiation exposure in the head and neck location, history of radiation exposure, history of burning of previously trauma and history of transplant or chronic immunosuppression [3]. Our case had no history of exposures. It is very important to diagnose this tumour correctly because, opposite to the other tumour with clear cells, CCAFX has usually a low potential for metastatic spread like AFX [8]. Despite the bizarre microscopic features that suggest high grade lesion, atypical fibroxanthomas are relatively indolent lesions that are usually cured by local excision. However, local recurrence may occur in some cases and metastasis is also quite rare. Factors that denoted aggressive behavior and possible metastasis in AFX are vascular invasion, extension into deep tissues, tumour necrosis, local recurrence, and history of immunosuppression [11]. There was no recurrence and metastasis during a one year follow-up of our case.

CONCLUSION

CCAFX is a rare variant of atypical fibroxanthoma that should be differentiated from other clear cell neoplasms of the skin or clear cell

sarcoma. In the differential diagnosis of these tumour CD10, CD68 and vimentin antibodies are important and should be evaluated with histopathological findings.

REFERENCES

- [1] Gru AA, Santa Cruz DJ. Atypical fibroxantoma: selective review. *Semin Diagn Pathol.* 2013;30:4-12.
- [2] Suárez-Vilela D, Izquierdo-García F, Domínguez-Iglesias F, Méndez-Álvarez JR. Combined papillated Bowen disease and clear cell atypical fibroxanthoma. *Case Rep Dermatol.* 2010;2:69-75.
- [3] Kemmerling R1, Dietze O, Müller S, Neureiter D. Aspects of the differential diagnosis of clear-cell lesions of the skin in connection with the rare case of a clear-cell atypical fibroxanthoma. *Pathol Res Pract.* 2009;205:365-70.
- [4] Crowson AN, Carlson-Sweet K, Macinnis C, Taylor JR, Battaglia T, LaMar WL, et al. Clear cell atypical fibroxanthoma: a clinicopathologic study. *J Cutan Pathol.* 2002;29:374-81.
- [5] Lazaro-Santander R, Andres-Gozalbo C, Rodriguez-Pereira C, Vera-Roman JM. Clear cell atypical fibroxanthoma. *Histopathology.* 1999; 35:484-5.
- [6] Smith-Zagone MJ, Prieto VG, Hayes RA, Timperman WW Jr, Diwan AH. HMB-45 (gp103) and MART-1 expression within giant cells in an atypical fibroxanthoma: a case report. *J Cutan Pathol.* 2004;3:284-6.
- [7] Cai JP, Randall B. HMB-45 expression in a clear cell variant of atypical fibroxanthoma. *J Cutan Pathol.* 2006 ;33:186-8.
- [8] Murali R, Pafreeman S. Clear-cell atypical fibroxantoma report of case with review of the literature. *J Cutan Pathol.* 2006;33:186-8.
- [9] Patterson JW1, Konerding H, Kramer WM. "Clear cell" atypical fibroxanthoma. *J Dermatol Surg Oncol.* 1987;13:1109-14.
- [10] L Requena, OP Sanguenza, YE Sanchez, V Furio. Clear-cell atypical fibroxanthoma: an uncommon histopathologic variant of atypical fibroxanthoma. *J Cutan Pathol.* 1997;24:176-82.
- [11] Helwing EB, May D. Atypical fibroxanthoma of the skin with metastasis. *Cancer.* 1986 ;57:368-76.

PARTICULARS OF CONTRIBUTORS:

1. Faculty, Department of Pathology, Recep Tayyip Erdogan University School of Medicine, Rize, Turkey.
2. Faculty, Department of Pathology lab, Bayburt State Hospital, Bayburt, Turkey.
3. Faculty, Department of Pathology, Recep Tayyip Erdogan University School of Medicine, Rize, Turkey.
4. Faculty, Department of Pathology, Recep Tayyip Erdogan University School of Medicine, Rize, Turkey.
5. Faculty, Department of Plastic and Reconstructive Surgery, Bayburt State Hospital, Bayburt, Turkey.

NAME, ADDRESS, E-MAIL ID OF THE CORRESPONDING AUTHOR:

Dr. Recep Bedir,
 Recep Tayyip Erdogan University of Medical Faculty, Department of Pathology, Rize-53000, Turkey.
 Phone: +90 464.2130491; Fax : + 90 464 2170364
 E-mail: bedirrecep@gmail.com

FINANCIAL OR OTHER COMPETING INTERESTS: None.

Date of Submission: **Feb 04, 2014**
 Date of Peer Review: **Mar 24, 2014**
 Date of Acceptance: **Apr 28, 2014**
 Date of Publishing: **Jun 20, 2014**