



Available online at www.sciencedirect.com

ScienceDirect

journal homepage: <http://www.kjms-online.com>



ORIGINAL ARTICLE

Comparison of the inguinal and scrotal approaches for the treatment of communicating hydrocele in children



Bilal Firat Alp^a, Hasan Cem Irkilata^{a,*}, Yusuf Kibar^a, Unal Zorba^b,
Ahmet Ali Sancaktutar^c, Engin Kaya^a, Murat Dayanc^a

^a Gulhane Military Medical Academy, Etlik, Ankara, Turkey

^b School of Medicine, Rize University, Rize, Turkey

^c School of Medicine, Dicle University, Diyarbakir, Turkey

Received 24 July 2013; accepted 9 September 2013

Available online 24 December 2013

KEYWORDS

Children;
Hydrocele;
Inguinal;
Scrotal;
Surgery

Abstract The inguinal approach is used for the treatment of hydrocele in the pediatric population. Although studies on scrotal orchiopexy have mentioned hernia or hydrocele repair through the same scrotal incision as a part of an orchiopexy procedure, there are a few studies reporting the treatment of isolated communicating hydrocele through a scrotal incision. We retrospectively evaluated and compared the outcomes of inguinal and scrotal approaches for the treatment of communicating hydrocele in boys. The classical inguinal and scrotal approaches to the treatment of communicating hydrocele were performed on 46 and 30 testicular units (in 43 boys and 27 boys, respectively). The patients' charts were reviewed to assess the operative times as well as the immediate and long-term complications during follow-up periods. The patients' ages ranged from 1 year to 8 years (3.6 ± 2.0 years) in the inguinal group and from 1 year to 10 years (mean 4.6 ± 2.8 years) in the scrotal group. Operative time was significantly lower in the scrotal group ($p < 0.0001$). The early minor complication rate did not differ between the two groups. Furthermore, there were no major complications noted. None of the patients had hydrocele recurrence after a mean follow-up of 6 months. The advantages of the scrotal approach for the treatment of communicating hydrocele are as follows: it is well tolerated, simple, and cosmetically appealing, and it has a short operative time in comparison with the standard inguinal approach. The scrotal incision technique is an effective alternative in communicating hydrocele treatment.

Copyright © 2013, Kaohsiung Medical University. Published by Elsevier Taiwan LLC. All rights reserved.

Conflicts of interest: All authors declare no conflicts of interest.

* Corresponding author. GATA Uroloji A.D., Etlik 06018 Ankara, Turkey.

E-mail address: hcirkilata@hotmail.com (H.C. Irkilata).

Introduction

The inguinal approach for the treatment of inguinoscrotal pathologies in children is the recommended standard surgical procedure. This surgical approach includes freeing the spermatic cord from the attached tissue, separating and high ligating the patent processus vaginalis (PPV). It is important to prevent vas and vessels injury when high ligating the PPV. Then, the testis is fixed to the scrotum without tension [1,2]. Inguinal exploration with a subsequent scrotal incision is also the gold standard for the treatment of palpable undescended testicles, but the single scrotal incision approach has gained popularity among pediatric urologists in the past two decades [3–14].

Two main concerns with the scrotal approach are that PPV may not be ligated high enough and proximal attachments may not be separated. Recently, scrotal incision orchiopexy has successfully been performed on palpable undescended testis both without PPV and with PPV [8,9,12–14]. Moreover, the scrotal approach has been used to correct other pathologies of PPV such as inguinal hernia and hydrocele [15–19]. In this article, we retrospectively reviewed and compared the surgical outcomes of transscrotal and inguinal approaches for boys with communicating hydrocele. In addition, we defined the technical details of the scrotal approach with illustrations and discuss its advantages and disadvantages.

Materials and methods

Seventy-six hydrocelectomies were performed on 70 children with communicating hydrocele between July 1993 and September 2011. The diagnosis of communicating hydrocele was based on clinical presentation, physical examination, and ultrasonographic findings. The main symptom in these children was a roundish, painless, and fluctuating mass in the upper scrotum. The mass size decreased while the children slept in a supine position overnight. The mass sizes increased during a Valsalva maneuver in older children and during straining or crying in infants. Manual palpating pressure on the mass reduced its size. Silk glove (or string) sign was positive in all children. Ultrasonography was used to distinguish the difficult cases. Patients with noncommunicating hydrocele or hernia were not included in this study.

Hydrocelectomies were performed using the inguinal approach on 46 testicular units (40 unilateral and 3 bilateral hydrocele) between July 1993 and September 2007. The scrotal approach has been performed since 2000 in our institution, leading a shift from the inguinal approach to the scrotal approach in hydrocele cases [9,14]. In accordance with this trend, hydrocelectomies were performed through the scrotal approach in 30 testicular units (24 unilateral and 3 bilateral hydrocele) between July 2002 and February 2012. We retrospectively reviewed the patients' charts to obtain the demographic data and postoperative outcomes including operative times, as well as the intraoperative, short-term, and long-term complications.

Surgical technique

After the induction of general anesthesia, we made a transverse scrotal incision along the crease of the scrotal

skin. This incision was then deepened through the layers of the scrotum down to the testis. Appropriate retractors were used to expose the superior level of the external ring (Fig. 1F). The upper wound edge was retracted in an upward direction in order to allow full visualization of the inguinal canal and the external inguinal ring.

At the beginning of the surgery, the testis and spermatic cord with the hydrocele sac were brought outside the scrotal incision (Fig. 1A). In order to separate the hydrocele sac from the spermatic cord easily, the sac was not opened during dissection, which was different from the classical technique (Figs. 1B, 2A-1 and A-2). In our practice, we opened the external spermatic fascia of spermatic cord from the side that is near the vessels and vas without the margin of hydrocele sac (Figs. 1C, 2B-1 and B-2). The hernia sac was separated bluntly from the other components of the spermatic cord (Fig. 1D and E). In the Trendelenburg position, the sac was dissected up to the external inguinal ring and "a caudal traction" on the sac provided an extra separation from the cord structures (Figs. 1F and 2C). The PPV was tied as cranially as possible using a 3–0 or 4–0 absorbable suture (Fig. 1G). When the distal part of the PPV (hydrocele sac) was divided, the proximal stump of PPV fell back into the peritoneal cavity (Fig. 2D). The testis was placed into the subdartos fascia of the scrotum. The scrotal skin was closed with a running subcutaneous absorbable suture (Fig. 1H).

Patients were discharged on the operation day or the day after the surgery. All patients came back to the clinic at least once within 4 weeks after the procedure to document any recurrence and also to ensure that no other complications had occurred. Thereafter, follow-up visits were performed in the 6th month.

Statistical analysis

The differences between inguinal and scrotal groups in terms of age, operative time, and immediate and late complications were analyzed with the Mann–Whitney *U* and Chi-square tests.

Results

The medical charts of 70 children with communicating hydrocele were retrospectively reviewed in this study. The inguinal group comprised 43 patients (40 unilateral and three bilateral), and the scrotal group consisted of 27 patients (24 unilateral and three bilateral). These patients' ages ranged from 1 year to 8 years (mean \pm SD, 3.6 ± 2.0 years) in the inguinal group and from 1 year to 10 years (4.6 ± 2.8 years) in the scrotal group (Table 1). There was no statistical difference between the two groups in terms of patient age. Operative time was statistically significantly lower in the scrotal group ($p < 0.0001$, Table 1). The most common early complication of scrotal hydrocelectomy was scrotal edema/induration, but there was no statistically significant difference in the total number of early complication between the inguinal and scrotal groups ($p = 0.416$, Table 1). As for hydrocele recurrence or testicular atrophy (late complications), both did not happen in either group. The overall success rate was 100% at the 6-month follow-up

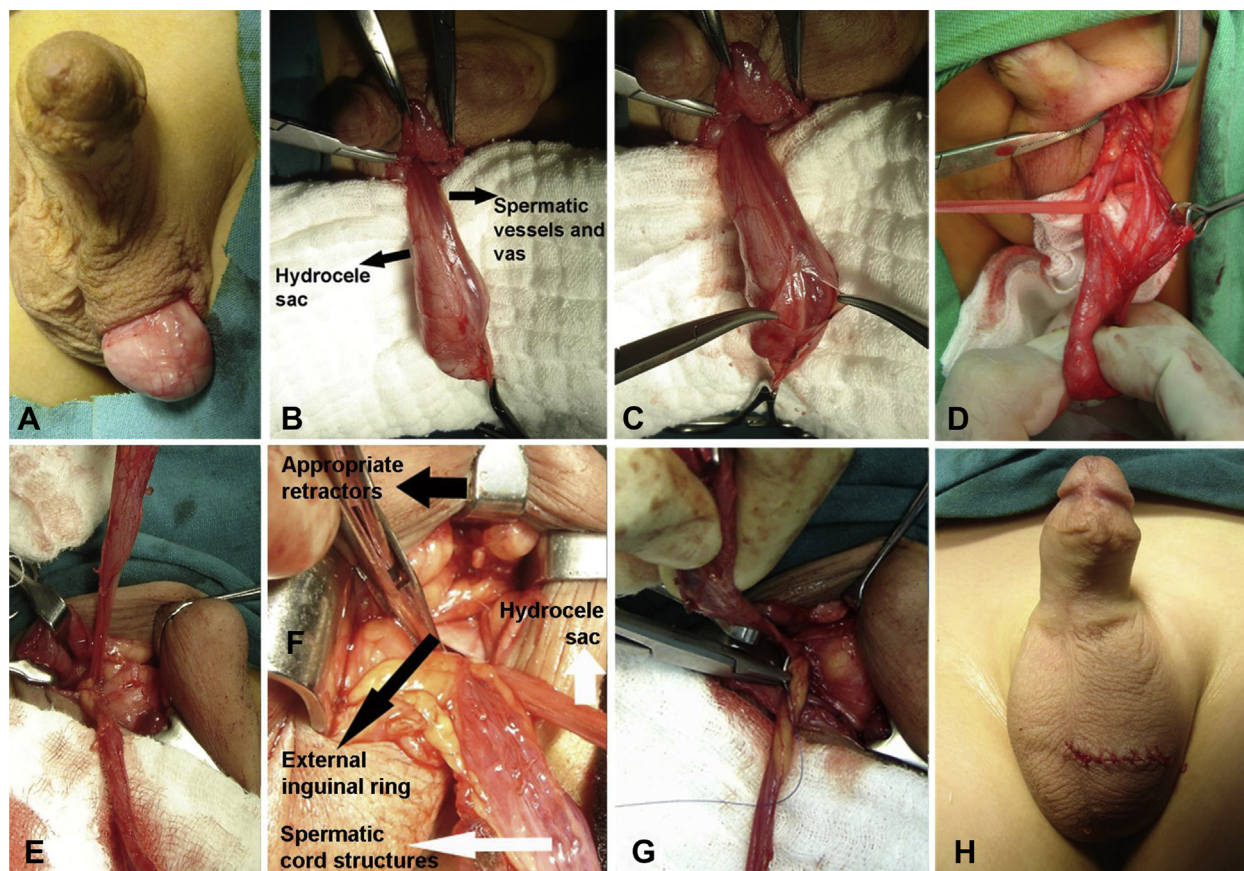


Figure 1. Surgical steps of the scrotal approach for the treatment of communicating hydrocele. (A) Scrotal components brought outside the scrotal incision. (B) Appearance of hydrocele sac, spermatic vessels, and vas deferens. (C) External spermatic fascia opened from the counterside of the hernia sac (from the side that was near the vessels and vas, but did not have any margin with hydrocele sac). (D) The hernia sac was separated bluntly from the other components of spermatic cord. (E) After Trendelenburg position, the sac was dissected up to the external inguinal ring and “a caudal traction” on the sac resulted in an extra separation from the cord structures. (F) External inguinal ring was seen (black long arrow). Flexibility of scrotal skin and appropriate retractors provided an excellent exposure of inguinal region (black short arrow). Hernia sac and other spermatic cord structures were seen (white arrows). (G) Patent processus vaginalis was tied as cranially as possible using a 3–0 or 4–0 absorbable suture. (H) The scrotal skin was closed with running subcuticular absorbable suture.

after both inguinal and scrotal hydrocelectomies. The scrotal scar was practically invisible after 4 weeks postoperatively (Fig. 3).

Discussion

The primary goal of the surgical treatment of communicating hydrocele in children is to ligate the PPV as cranially as possible, with no iatrogenic injury and postoperative recurrence. Inguinal incision has been accepted as an unchangeable route in the pediatric population for the treatment of communicating hydrocele and indirect inguinal hernia [20]. However, the transscrotal approach for the treatment of palpable undescended testis was introduced by Bianchi and Squire in 1989 [3]. It has also been recommended for nonpalpable testis by Snodgrass in order to reduce the necessity for diagnostic laparoscopy [21]. Since the late 1980s, the scrotal approach has been used as an alternative for the management of undescended testis with or without hernia or other inguinoscrotal pathologies [4]. The advantages of the scrotal approach are

less postoperative pain, reduced operation time, and good cosmetic appearance. Recently published studies on scrotal orchiopexy reported that PPV could be dissected from the cord structures through the inguinal canal with the aid of the traction of the sac, and after the division, the proximal aspect of PPV invariably retracted to the internal inguinal ring [8–13]. Moreover, five studies reported successful results when the scrotal approach was used for children with hernias and hydroceles [15–19]. No recurrence was identified in four of the five studies [16–19], and the overall success rate was 99.5% in these five studies [15–19]. According to these studies, the length of the inguinal canal in children is very short; thus, disruption to the integrity of the inguinal canal is not necessary [15–19]. The traction on the sac provides a ligation of the PPV at the level of the internal ring [15,17]. However, for a child with an undescended testicle and inguinal hernia, we had to convert to inguinal incision because of proximal bleeding after ligation and division of the PPV. In this child, we opened the inguinal canal completely and saw that the stump of the PPV was beyond the internal ring.

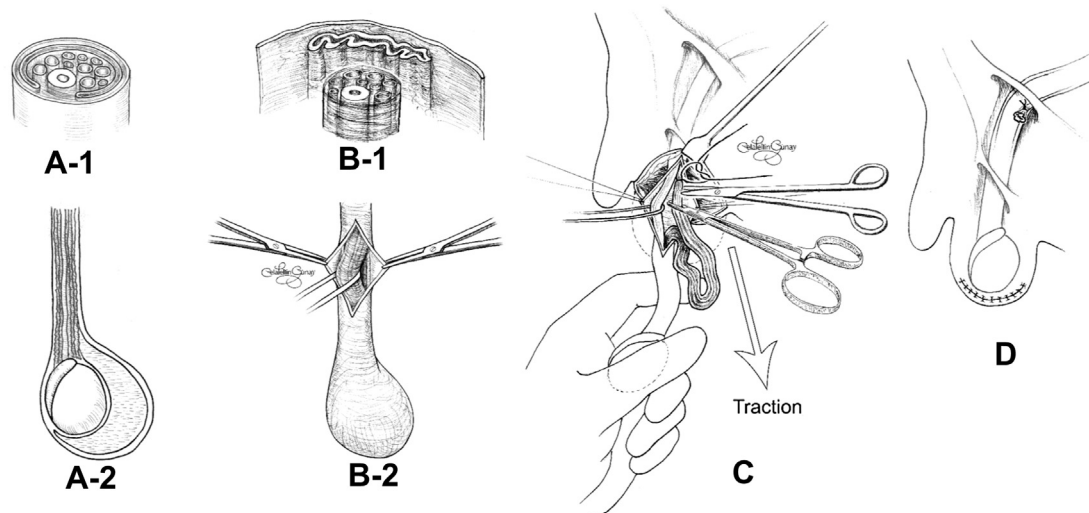


Figure 2. Illustrations for scrotal hydrocelectomy. (A-1 and A-2) Vertical and horizontal normal appearance of the hydrocele sac. (B-1 and B-2) Vertical and horizontal appearance of separation of hernia sac from other components of the spermatic cord. (C) Hernia sac was dissected up to the external inguinal ring and "a caudal traction" on the sac provided an extra separation from the cord structures. (D) Traction of the sac was simultaneously ended and the proximal part of processus vaginalis fell back into the peritoneal cavity. The divided hydrocele sac was seen.

PPV was classified as closed, partially closed, or open depending on the level of communication or obliteration from the internal ring to the testis [22]. However, processus vaginalis was considered patent by Rowe et al. if the length from the internal inguinal ring was 2 cm or longer [23]. Even

more important than these definitions is how the PPV can be dissected from the spermatic cord more easily, and whether the dissection could be made proximal enough in the scrotal approach. These are the two main questions that need to be answered.

Classically, the PPV is dissected from the spermatic cord on the inner side of the sac. However, this maneuver is performed adjacent to the cord and may tear the sac while surgeons are dissecting the spermatic vessels and vas, which can cause difficulties while ligating and separating the proximal part of the PPV. To avoid these problems, we dissect the sac without opening it. The anatomic relation between the cord and the sac makes the aforementioned method feasible. Because tunica vaginalis does not cover the cord 360°, we can start the dissection from the external spermatic fascia where the tunica vaginalis does not surround the vas and vessels (Fig. 1C).

In the past 20 years that scrotal approach has been used to treat the undescended testis, it has been asserted that the associated PPV could be ligated high enough [8,9,12–14]. Although the classical inguinal approach is recommended for the treatment of communicating hydrocele [24], there is one study (apart from ours) that compares inguinal hydrocelectomy and scrotal hydrocelectomy [19]. Through spermatic cord caudal traction during scrotal approach, we could ligate the highest PPV without damaging the inguinal canal integrity (Fig. 2C and D). In this series, no difference was noted in regard to complication and recurrence rate between scrotal and inguinal approaches.

The scrotal approach avoids tampering with the inguinal canal and offers an excellent access to the PPV with minimal dissection and morbidity [18]. Additionally, this approach eliminates the risk of damage to the ilioinguinal and genitofemoral nerves [18]. All of these factors provide less postoperative pain, shorter hospital stay, and faster healing compared to the inguinal approach [15–19].

Table 1 Demographic characteristics of children with communicating hydrocele and immediate/late complications of inguinal and scrotal hydrocelectomies.

Parameter	Inguinal approach	Scrotal approach	<i>p</i>
No. of procedures/ patients, <i>n/n</i>	46/43	30/27	
Age, y			
Mean ± SD (range)	3.6 ± 2.0 (1–8)	4.6 ± 2.8 (1–10)	0.186
Operative time, min			
Mean (range)	45.9 (34–66)	26.2 (20–36)	<0.0001
Pre-postoperative immediate Complications, <i>n</i>			0.416
Vascular injury	2	1	
Scrotal edema/ induration	0	4	
Scrotal hematoma	0	0	
Wound infection	2	0	
Orchitis/epididymitis	2	1	
Overall minor complications	6	6	
Late complications, <i>n</i>			1
Recurrence	0	0	
Testicular atrophy	0	0	

SD = standard deviation.

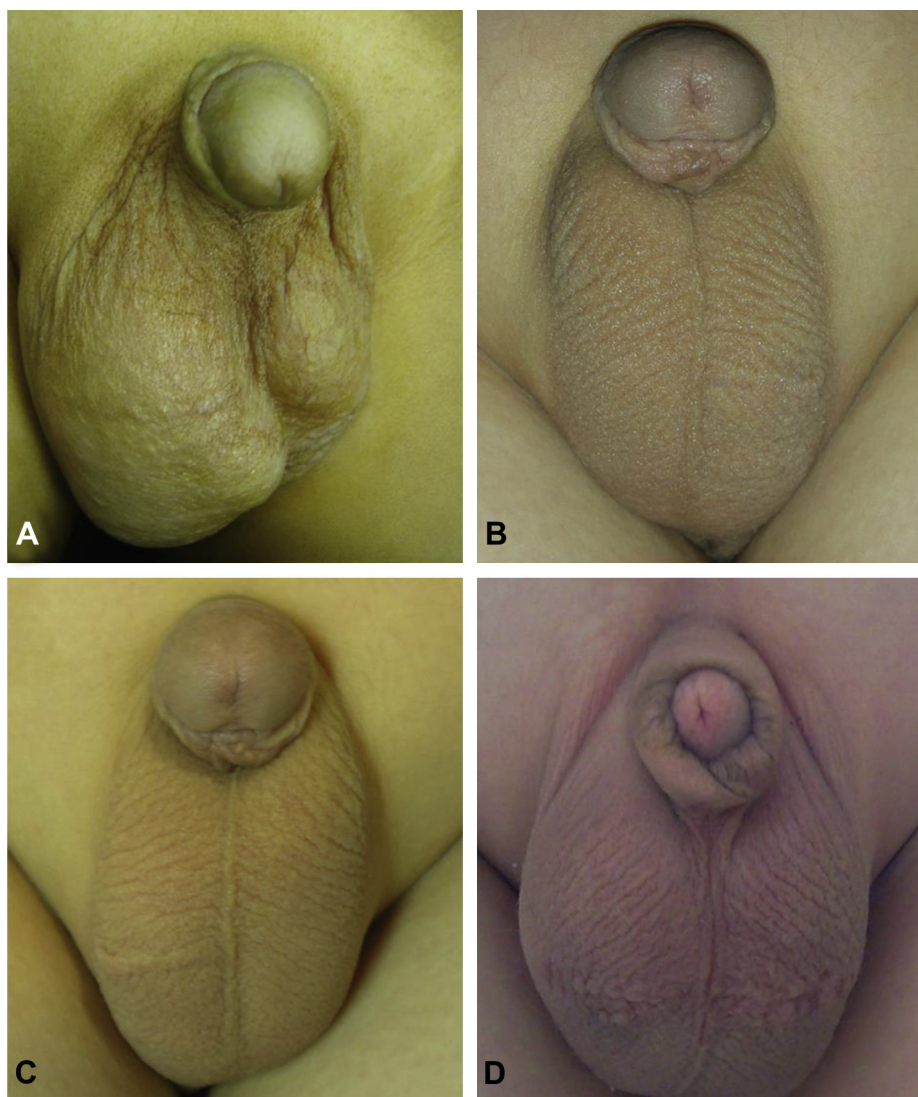


Figure 3. Pre- and postoperative appearances. (A) Preoperative appearance of the right hydrocele. (B and C) Unilateral left and right side scrotal incision scars, 6 months after hydrocelectomy. (D) Bilateral scrotal incision scars, 6 months after hydrocelectomy.

Another obvious advantage of the scrotal approach is the excellent cosmesis [15–19]. In most cases, the scar is nearly invisible [18,19]. Koyle et al. [17] noted another advantage of the scrotal approach, in that it allows access to the scrotal contents and removal of the distal portion of tunica vaginalis [17]. Inspection of the scrotal contents reduces the risk of subsequent noncommunicating hydrocele, and also removes the risk of possible acute scrotal hematoma and allows the excision of vestigial appendages [17]. Using scrotal incision in the scrotal skin fold resulted in shorter operative times, decreased pain, and improved cosmesis in our patients. To our knowledge, there are three reasonably different scrotal locations to incise the scrotum: the scrotal–inguinal crease, midline scrotal, and transverse to rugae of scrotum. A midline scrotal incision may improve the cosmetic outcome, especially in bilateral cases [17].

The use of the scrotal approach for patients with hydrocele is associated with several disadvantages. One of its drawbacks is that children with unilateral hydrocele are at risk of contralateral PPV [17]. Moreover, children with

direct inguinal hernia cannot be treated through this incision. Furthermore, the scrotal approach may cause scrotal edema, which is the most common early postoperative complication. However, it is temporary and can be treated with anti-inflammatory drugs [25].

The laparoscopic approach is another option for the treatment of a hernia and hydrocele in children. It allows checking and repairing the hernias in both groins [20]. However, a recent meta-analysis on pediatric inguinal hernia reported that the laparoscopic approach is associated with a trend toward a higher recurrence rate and longer operative time for unilateral repairs, but shorter operative time for bilateral repairs [26]. Recently, laparoscopic hydrocelectomy in the pediatric age group has been reported [27,28]. However, the laparoscopic operation time was longer than that of scrotal hydrocelectomy, and the incision scars probably were more noticeable than the scrotal incision scars. Moreover, the cost it incurred was higher than that of the scrotal approach.

In conclusion, the scrotal approach for the treatment of communicating hydrocele in children may be an alternative technique in experienced centers. The main advantages of this technique are cosmesis and shortened operative time. However, the most common early complication is temporary scrotal edema. This technique provides an easy approach to the anatomic structures involved in scrotal and groin pathologic features without disruption of the inguinal canal integrity. The need for wound edge retraction is lower, and hence fewer traumas are caused to the inguinal region.

References

- [1] Bevan AD. Operation on undescended testicle and congenital inguinal hernia. *JAMA* 1899;33:773.
- [2] Hutcheson JC, Cooper CS, Snyder 3rd HM. The anatomical approach to inguinal orchiopexy. *J Urol* 2000;164:1702–4.
- [3] Bianchi A, Squire BR. Trans-scrotal orchidopexy: orchidopexy revised. *Pediatr Surg Int* 1989;4:189.
- [4] Misra D, Dias R, Kapila L. Scrotal fixation: a different surgical approach in the management of the low undescended testes. *Urology* 1997;49:762–5.
- [5] Caruso AP, Walsh RA, Wolach JW, Koyle MA. Single scrotal incision orchiopexy for the palpable undescended testicle. *J Urol* 2000;164:156–9.
- [6] Parsons JK, Ferrer F, Docimo SG. The low scrotal approach to the ectopic or ascended testicle: prevalence of a patent processus vaginalis. *J Urol* 2003;169:1832–3.
- [7] Russinko PJ, Siddiq FM, Tackett LD, Caldamone AA. Prescrotal orchiopexy: an alternative surgical approach for the palpable undescended testis. *J Urol* 2003;170:2436–8.
- [8] Bassel YS, Scherz HC, Kirsch AJ. Scrotal incision orchiopexy for undescended testes with or without a patent processus vaginalis. *J Urol* 2007;177:1516–8.
- [9] Dayanc M, Kibar Y, Irkilata HC, Demir E, Tahmaz L, Peker AF. Long-term outcome of scrotal incision orchiopexy for undescended testis. *Urology* 2007;70:786–8.
- [10] Irkilata HC, Dayanc M, Kibar Y, Musabak U, Yesilkaya E, Oral E, et al. Effect of scrotal incision orchiopexy on serum inhibin B levels and comparison with classic inguinal orchiopexy. *Urology* 2008;72:525–9.
- [11] Al-Mandil M, Khoury AE, El-Hout Y, Kogon M, Dave S, Farhat WA. Potential complications with the prescrotal approach for the palpable undescended testis? A comparison of single prescrotal incision to the traditional inguinal approach. *J Urol* 2008;180:686–9.
- [12] Callewaert PR, Rahnama'i MS, Biallostowski BT, van Kerrebroeck PE. Scrotal approach to both palpable and impalpable undescended testes: should it become our first choice? *Urology* 2010;76:73–6.
- [13] Yucel S, Celik O, Kol A, Baykara M, Guntekin E. Initial prescrotal approach for palpable cryptorchid testis: results during a 3-year period. *J Urol* 2011;185:669–72.
- [14] Cloutier J, Moore K, Nadeau G, Bolduc S. Modified scrotal (Bianchi) mid raphe single incision orchiopexy for low palpable undescended testis: early outcomes. *J Urol* 2011;185:1088–92.
- [15] Iyer KR, Kumar V, Huddart SN, Bianchi A. The scrotal approach. *Pediatr Surg Int* 1995;10:58–60.
- [16] Lais A, Ferro F. Trans-scrotal approach for surgical correction of cryptorchidism and congenital anomalies of the processus vaginalis. *Eur Urol* 1996;29:235.
- [17] Koyle MA, Walsh R, Caruso A, Wilson E. Scrotal (Bianchi) approach to patent processus vaginalis in children. *Tech Urol* 1999;5:95–9.
- [18] Fearne Ch, Abela M, Aquilina D. Scrotal approach for inguinal hernia and hydrocele repair in boys. *Eur J Pediatr Surg* 2002;12:116–7.
- [19] Gökçora IH, Yagmurlu A. A longitudinal follow-up using the high trans-scrotal approach for inguinal and scrotal abnormalities in boys. *Hernia* 2003;7:181–4.
- [20] Lau ST, Lee YH, Caty MG. Current management of hernias and hydroceles. *Semin Pediatr Surg* 2007;16:50–7.
- [21] Snodgrass WT, Yucel S, Ziada A. Scrotal exploration for unilateral nonpalpable testis. *J Urol* 2007;178:1718–21.
- [22] Barthold JS, Redman JF. Association of epididymal anomalies with patent processus vaginalis in hernia, hydrocele and cryptorchidism. *J Urol* 1996;156:2054–6.
- [23] Rowe MI, Copelson LW, Clatworthy HW. The patent processus vaginalis and the inguinal hernia. *J Pediatr Surg* 1969;4:102–7.
- [24] Wilson JM, Aaronson DS, Schrader R, Baskin LS. Hydrocele in the pediatric patient: inguinal or scrotal approach? *J Urol* 2008;180:1724–7.
- [25] Ceylan K, Yuksel Y, Hasan G, Alpaslan K. Inguinal approach in adult hydrocele surgery: preliminary randomized study. *Adv Ther* 2006;23:159.
- [26] Yang C, Zhang H, Pu J, Mei H, Zheng L, Tong Q. Laparoscopic vs open herniorrhaphy in the management of pediatric inguinal hernia: a systemic review and meta-analysis. *J Pediatr Surg* 2011;46:1824–34.
- [27] Ho CH, Yang SS, Tsai YC. Minilaparoscopic high-ligation with the processus vaginalis undissected and left in situ is a safe, effective, and durable treatment for pediatric hydrocele. *Urology* 2010;76:134–7.
- [28] Martin K, Emil S, Laberge JM. The value of laparoscopy in the management of abdominoscrotal hydroceles. *J Laparoendosc Adv Surg Technol A* 2012;22:419–21.