

# An Unexpected Cause of Diffuse Alveolar Hemorrhage in an Immunocompetent Young Patient: Herpes Simplex Type 1 Related Pneumonia

## İmmunitesi Sağlam Genç Bir Hastada Beklenmedik Sebebe Bağlı Diffüz Alveoler Hemoraji; Herpes Simplex Tip-1 İlişkili Pnömoni

Mevlüt Karataş<sup>1</sup>, Halit Çınarka<sup>1</sup>, Servet Kayhan<sup>1</sup>, Aziz Gümüş<sup>1</sup>, Recep Bedir<sup>2</sup>, Songül Özyurt<sup>1</sup>, Ünal Şahin<sup>1</sup>

### Abstract

An 18-year-old man was admitted to the hospital with the complaints of dyspnea, cough and hemoptysis. The physical examination revealed, herpes labialis on the lower lip and crackles in the middle and lower regions of both lungs. Laboratory tests revealed a leukocyte count of 21.700/mm<sup>3</sup>, hemoglobin level of 6.80 g/dL, hematocrit of 23.2%, CRP of 5.46 mg/dl, and HSV-1 IgM was positive. The thorax CT revealed bilateral and diffuse ground glass appearance and interlobular septal thickening on both pulmonary parenchymal areas. Active bleeding was observed in the entire tracheobronchial system by bronchoscopy. Microscopic images showed hemosiderin-loaded macrophages. We diagnosed HSV-1 related pneumonia and diffuse alveolar hemorrhage (DAH). We treated the patient with acyclovir, corticosteroid, erythrocyte suspension, cryoprecipitate, and tranexamic acid. The patient improved dramatically. Finally, while HSV-1 related pneumonia is usually seen in immunocompromised hosts and critically ill patients, in the present case, a healthy immunocompetent man was infected with HSV-1. Following medication, the patient was completely healed. We think that the current case is a rare disease of HSV-1 leading to DAH.

**Key words:** Herpes simplex virus, pneumonia, diffuse alveolar hemorrhage.

### Özet

On sekiz yaşında erkek hasta nefes darlığı, öksürük, kanlı balgam şikâyetiyle hastanemize başvurdu. Fizik bakıda vital bulguları normaldi. Alt dudakta herpes labialis ve akciğerler orta-alt bölgede inspiratuar raller mevcuttu. Laboratuvarında lökosit 21.700/mm<sup>3</sup>, hemoglobin 6,80 g/dL, hematokrit %23,2, CRP 5,46mg/dl ve viral panelinde HSV-1 IgM pozitifliği. Toraks BT'de her iki akciğerde diffüz buzlu cam opasitesi, interlobuler septal kalınlaşmalar görülmekteydi. Fiberoptik bronkoskopiye trakeobronşial sistemde diffüz eritem ve kanama saptandı. Bronkoalveoler lavajda hemosiderin yüklü makrofajlar görüldü. HSV-1'e bağlı pnömoni ve diffüz alveoler hemoraji (DAH) düşünülen hastaya acyclovir, kortikosteroid, eritrosit süspansiyonu, taze donmuş plazma ve traneksamik asit başlandı. Tedaviye dramatik cevap gelişti. Sonuç olarak, HSV-1 pnömonisinin sıklıkla immün suprese ve yoğun bakım hastalarında görüldüğü bilinmesine karşın olgumuzda immünitesi normal, genç bir hastada HSV-1'e bağlı pnömoni ve DAH kliniğinin geliştiğini görmekteyiz. Bu olgunun HSV-1'e bağlı gelişen, DAH patolojisiyle seyreden ve seyrek görülen bir olgu olduğu kanısındayız.

**Anahtar Sözcükler:** Herpes simplex virus, pnömoni, diffüz alveoler hemoraji.

<sup>1</sup>Department of Pulmonology, Recep Tayyip Erdoğan University Faculty of Medicine, Rize, Turkey

<sup>2</sup>Department of Pathology, Recep Tayyip Erdoğan University Faculty of Medicine, Rize, Turkey

<sup>1</sup>Recep Tayyip Erdoğan Üniversitesi Tıp Fakültesi, Göğüs Hastalıkları Anabilim Dalı, Rize

<sup>2</sup>Recep Tayyip Erdoğan Üniversitesi Tıp Fakültesi Patoloji Anabilim Dalı, Rize

Submitted (Başvuru tarihi): 15.10.2014 Accepted (Kabul tarihi): 28.11.2014

**Correspondence (İletişim):** Mevlüt Karataş, Department of Pulmonology, Recep Tayyip Erdoğan University Faculty of Medicine, Rize, Turkey  
e-mail: fmkaratas@yahoo.com

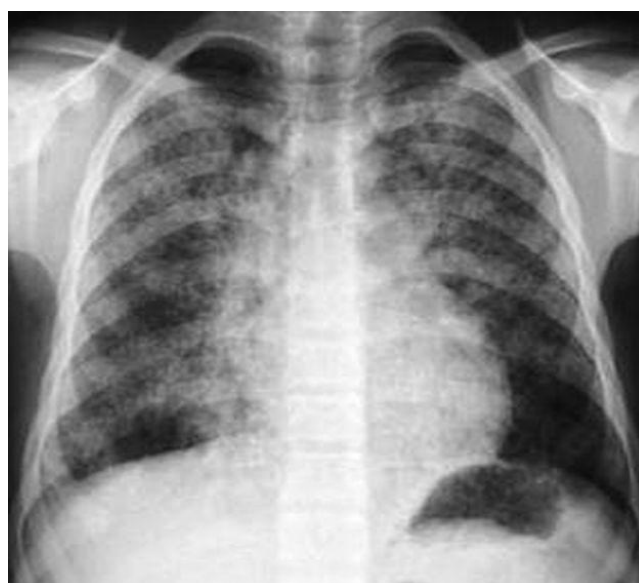

A variety of pulmonary pathologies may cause diffuse alveolar hemorrhage (DAH) which is a life-threatening clinical entity and requires urgent treatment. DAH often results in acute respiratory failure that requires early diagnosis and aggressive treatment. The diagnosis of DAH is difficult. DAH originates from the pulmonary microvasculature and responsible to alveolar damage. There are many conditions that can cause DAH. Most etiologies share a common pathophysiologic theme: damage to the alveolar microcirculation; any source of injury to the alveolar microcirculation can cause alveolar hemorrhage. Most patients present with dyspnea, cough, hemoptysis, and new alveolar infiltrates on chest imaging. Autoimmune disorders are the most frequent cause of DAH (1). Pulmonary infections can also cause DAH. HSV-1 causes a variety of infections that involve the upper and lower air way. HSV-1 related pneumonia showed especially in immunocompromised patients. We report a case of community acquired pneumonia related to Herpes simplex type 1 virus (HSV-1) presented with a clinical table of diffuse alveolar hemorrhage.

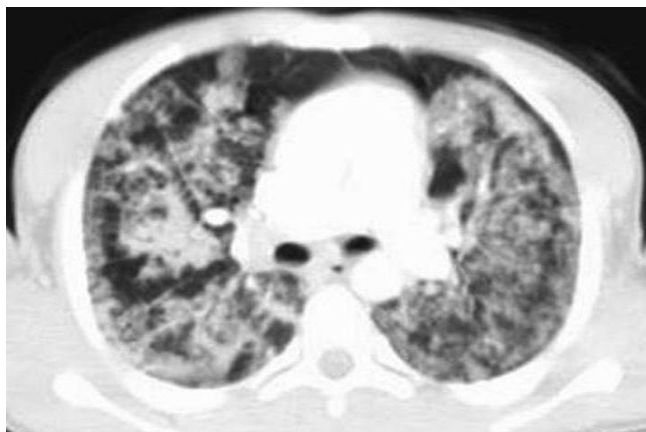## CASE

An 18-year-old young man was admitted to our emergency department with the complaints of cough, episodic bloody sputum, fatigue, and progressive dyspnea for two days. The patient was a non-smoker and there was no specific disease in his medical history. The physical examination revealed a 37.2 °C fever, oxygen saturation on room air of 86%, heart rate of 138/min, respiratory rate of 14 breaths/min, herpes labialis on the lower lip, and crackles in middle and lower regions of both lungs. Laboratory tests revealed a white blood cell count of 21.700/mm<sup>3</sup> with neutrophilic predominance and lymphopenia, hemoglobin level of 6.80 g/dL, hematocrit of 23.2%, platelet count of 172.000 K/uL, serum creatinine level of 0.58 mg/dL, LDH of 500 U/L, troponin level of 0.08 ng/ml, erythrocyte sedimentation rate of 16mm/hour, and urine analysis was normal. The coagulation study revealed a mildly elevated prothrombin time of 17.9 sec. and partial thromboplastin time of 30.8 sec. The rheumatologic workup, including all of the antinuclear antibodies, anti-double stranded antibodies, antineutrophil cytoplasmic antibodies, and anti-glomerular basement membrane antibodies were negative. Serological tests were as follows: C-reactive protein: 5.46 mg/dl, rheumatoid factor: less than 20 IU/mL, and the brucella test was negative. ELISA tests, including HBsAg, anti-HBs, anti-HCV, anti-HIV, anti-toxo IgM, anti-CMV IgM, EBV

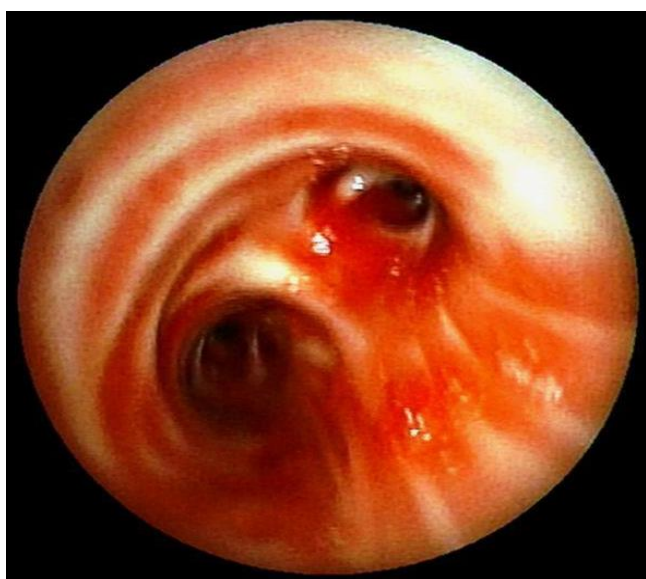VCA IgM, Herpes simplex type 2 IgG, and Herpes simplex type 2 IgM were negative. Anti-toxo IgG, anti-CMV IgG, EBV EBNA IgG, HSV-1 IgM and HSV-1 IgG were positive. There were no bacteria in the sputum culture. The chest x-ray revealed bilateral alveolar infiltrations (Figure 1). The computed tomography revealed diffuse ground-glass opacities and interlobular septal thickening on both pulmonary parenchymal areas (Figure 2). Diffuse erythema and bleeding were observed by fiberoptic bronchoscopy in the tracheobronchial system (Figure 3). Bronchoalveolar lavage of the left lower lobe showed progressively bloody return, consistent with alveolar hemorrhage. The microbiologic and cytological examination revealed no evidence of infection or malignancy. There were no bacteria in the bronchoalveolar lavage culture. Microscopic images of bronchoalveolar lavage showed hemosiderin loaded macrophages and inflammatory cells (Figure 4). All of the radiologic and laboratory results were consistent with the diagnosis of HSV-1 related pneumonia. Therefore, we administered medical treatment with intravenous administrations of acyclovir (500 mg 2x1), high dose corticosteroid (methylprednisolone, 120 mg), erythrocyte suspension, cryoprecipitate, and tranexamic acid (250 mg, 4x1) to prevent bleeding from the endobronchial system. The patient responded to medical therapy. Clinical and biochemical parameters of the patient improved dramatically. During the medical follow up period, there was no fever, dyspnea, or bloody sputum. Pulmonary function and radiologic findings gradually recovered. After eleven days of treatment, control chest x-ray, and computed tomography were shown as healing images in the pulmonary parenchymal areas.



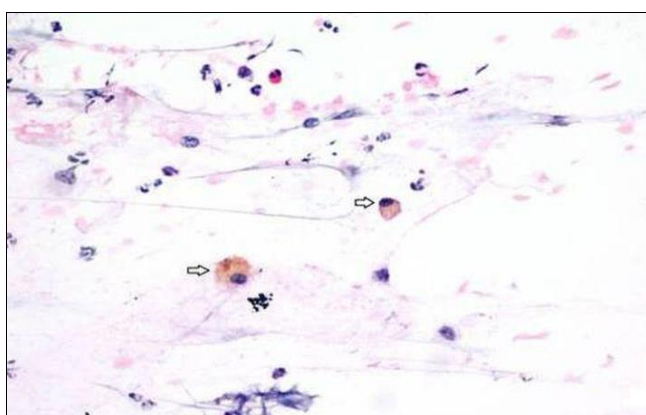
**Figure 1:** Initial chest x-ray showed bilateral alveolar infiltrates



**Figure 2:** Thoracic computed tomography showed bilateral, diffuse ground glass opacities and interlobular septal thickening



**Figure 3:** Fiberoptic bronchoscopy revealed diffuse airway erythema and bleeding



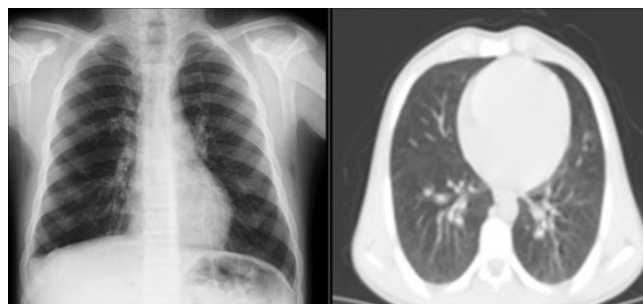
**Figure 4:** Inflammatory cells, respiratory tract epithelial cells and hemosiderin loaded macrophages (black arrow) were observed in the cytological examination of the bronchial lavage obtained by bronchoscopy (H&Ex440)

## DISCUSSION

Diffuse alveolar hemorrhage (DAH) is a life-threatening condition caused by a diverse group of disorders. DAH

originates from the pulmonary microcirculation including alveolar capillaries, arterioles, and venules. The underlying disease mechanism may be either pulmonary specific (e.g.: diffuse alveolar damage, or infections) or more generalized (vasculitis) (1).

Herpes simplex infections are very common in the human population. HSV-1 causes a variety of infections that involve mucocutaneous surfaces, the central nervous system, and occasionally visceral organs such as the lungs (2,3). HSV-2 mostly causes Herpes genitalis, and at the same time may be recognized in 10% to 20% of cases in Herpes labialis (4). Primary HSV infections are seen usually in the upper respiratory system as gingivostomatitis or pharyngitis. Some viruses of the herpes virus family, such as HSV (e.g.: types 1, 2, 6, and 8), Varicella zoster, and CMV can cause pneumonia (5).



**Figure 5:** Fiberoptic bronchoscopy revealed diffuse airway erythema and bleeding

Herpes simplex virus-related pneumonia is primarily caused by HSV-1 and rarely caused by HSV-2 (6,7). Humoral and cell-mediated immunity act in response to HSV-1 infections. The most severe HSV-1 disease occurs in immunocompromised host (e.g.: the elderly; bone marrow transplant recipients; or patients with severe pulmonary disease or Human immunodeficiency virus infections); and critically ill patients (8,9). Published reports of HSV pneumonia are based on autopsy cases because of false diagnosis and high mortality among untreated patients (10).

The herpes simplex virus may reach the lungs through three different means. The contiguous spread to the lower respiratory tract, aspiration of HSV, or oropharyngeal lesions may play a role in many cases (11). Pathologically, HSV infection can have three main forms of pulmonary involvement: necrotizing tracheobronchitis, necrotizing pneumonia, and interstitial pneumonitis (12). The interstitial pneumonitis form of HSV pulmonary infection is characterized by diffuse alveolar damage consisting of interstitial lymphocytic infiltration, alveolar hemorrhage, and hyaline membrane formation (13). Computed tomogra-

phy findings of HSV pneumonia are diffuse or multifocal ground glass attenuation, peribronchial consolidation, or a mixed pattern of both findings (6,7).

In our case, sputum and bronchoalveolar lavage cultures were negative for microbiological growth. HSV-1 IgM and HSV-1 IgG were positive in the ELISA tests. Additionally, the physical examination of the patients revealed Herpes labialis on the lower lip. Computed tomography findings were compatible with HSV-1 related pneumonia. Although many conditions can cause DAH, all diagnostic steps were taken to diagnose HSV-1 related pneumonia and resulted diffuse alveolar hemorrhage. Antiviral treatment was administered and radiological and clinical healing were dramatically observed.

As conclusion; In this case, an 18-year-old healthy young man was infected by HSV-1, which resulted in serious pneumonia and diffuse alveolar hemorrhage. While some published papers showed that HSV-1 infection can usually cause pneumonia in immunocompromised hosts and critically ill patients, in the present case, a healthy/immunocompetent man was infected by HSV-1, which resulted in diffuse alveolar hemorrhage. After taking antiviral medication, the patient completely covered, as revealed in both the chest x-ray and computing tomography images (Figure 5). We believe that the current case is a rare disease of HSV-1 leading to DAH.

## CONFLICTS OF INTEREST

None declared.

## AUTHOR CONTRIBUTIONS

Concept - M.K., A.G., R.B., H.Ç., Ü.Ş., S.K., S.Ö.; Planning and Design - M.K., S.K., S.Ö., A.G., H.Ç., Ü.Ş., R.B.; Supervision - M.K., A.G., R.B., H.Ç., Ü.Ş., S.K., S.Ö.; Funding - M.K., R.B., Ü.Ş.; Materials - M.K., S.K., R.B.; Data Collection and/or Processing - M.K., R.B.; Analysis and/or Interpretation - M.K., S.K., H.Ç.; Literature Review - M.K., S.Ö.; Writing - M.K.; Critical Review - Ü.Ş., S.Ö.

## YAZAR KATKILARI

Fikir - M.K., A.G., R.B., H.Ç., Ü.Ş., S.K., S.Ö.; Tasarım ve Dizayn - M.K., S.K., S.Ö., A.G., H.Ç., Ü.Ş., R.B.; Denetim - M.K., A.G., R.B., H.Ç., Ü.Ş., S.K., S.Ö.; Kaynaklar - M.K., R.B., Ü.Ş.; Malzemeler - M.K., S.K., R.B.; Veri Toplama ve/veya İşleme - M.K., R.B.; Analiz ve/veya Yorum - M.K., S.K., H.Ç.; Literatür Taraması - M.K., S.Ö.; Yazıyı Yazan - M.K.; Eleştirel İnceleme - Ü.Ş., S.Ö.

## REFERENCES

1. Collard HR, Schwarz MI. Diffuse alveolar hemorrhage. *Clin Chest Med* 2004; 25:583-92. [\[CrossRef\]](#)
2. Corey L. Herpes simplex virus. In: Mandell GL, Bennett JE, Dolin R, eds, *Principles and practice of infectious diseases*, 5th ed. Philadelphia, PA: Churchill Livingstone, 2000; 1564–80.
3. Whitley RJ, Roizman B. Herpes simplex viruses. In: Richman DD, Whitley RJ, Hayden FG, eds, *Clinical virology*, 2nd edn. Washington, DC: ASM Press, 2002; 375–401.
4. Feldman S, Stokes DC. Varicella zoster and herpes simplex virus pneumonias. *Semin Respir Infect* 1987; 2:84–94.
5. Miyazato A, Kishimoto H, Tamaki K, Nakama K, Saito A. Herpes simplex bronchopneumonia in a non-immunocompromised individual. *Intern Med* 2001; 49:836–40.
6. Aquino SL, Dunagan DP, Chiles C, Haponik EF. Herpes simplex virus 1 pneumonia: patterns on CT scans and conventional chest radiographs. *J Comput Assist Tomogr* 1998; 22:795–800. [\[CrossRef\]](#)
7. Gasparetto EL, Escuissato DL, Inoue C, Marchiori E, Müller NL. Herpes simplex virus type 2 pneumonia after bone marrow transplantation: high-resolution CT findings in 3 patients. *J Thorac Imaging* 2005; 20:71–3.
8. Corey L, Spear PG. Infections with herpes simplex viruses (1). *N Engl J Med* 1986; 314:686–91. [\[CrossRef\]](#)
9. Wilton JM, Ivanyi L, Lehner T. Cell-mediated immunity in Herpesvirus hominis infections. *Br Med J* 1972; 1: 723–6. [\[CrossRef\]](#)
10. Martinez E, de Diego A, Paradis A, Perpiñá M, Hernandez M. Herpes simplex pneumonia in a young immunocompetent man. *Eur Respir J* 1994; 7:1185–8.
11. Nash G. Necrotizing tracheobronchitis and bronchopneumonia consistent with herpetic infection. *Hum Pathol* 1972; 3:283–91. [\[CrossRef\]](#)
12. Travis WD, Colby TV, Koss MN, Rosado-de Christenson, ML, Muller NL, King TE. *Non-neoplastic disorders of the lower respiratory tract*. Washington DC, USA: American Registry of Pathology, 2002.
13. Ramsey PG, Fife KH, Hackman RC, Meyers JD, Corey L. Herpes simplex virus pneumonia: clinical, virologic, and pathologic features in 20 patients. *Ann Intern Med* 1982; 97:813–20. [\[CrossRef\]](#)