

# Biochemical and Histopathological Investigation of Liver Tissues on High Fat Diet Fed Rats

## Yüksek Yağ İçerikli Diyetle Beslenmiş Sıçanların Karaciğer Dokularının Histokimyasal ve Biyokimyasal İncelenmesi

• Tuğba Çelik Samancı<sup>1</sup>, • Alpaslan Gökçimen<sup>2</sup>, • Tunçay Kuloğlu<sup>3</sup>, • Murat Boyacıoğlu<sup>4</sup>, • Yurdun Kuyucu<sup>5</sup>, • Sait Polat<sup>5</sup>

<sup>1</sup>Recep Tayyip Erdoğan University Faculty of Medicine, Department of Histology and Embryology, Rize, Turkey

<sup>2</sup>Aydın Adnan Menderes University Faculty of Medicine, Department of Histology and Embryology, Aydın, Turkey

<sup>3</sup>Fırat University Faculty of Medicine, Department of Histology and Embryology, Elazığ, Turkey

<sup>4</sup>Aydın Adnan Menderes University Faculty of Veterinary, Department of Pharmacology and Toxicology, Aydın, Turkey

<sup>5</sup>Çukurova University Faculty of Medicine, Department of Histology and Embryology, Adana, Turkey



### Abstract

**Objective:** Hepatic steatosis is a common cause of liver disease and has become more prevalent recently. This study was conducted to investigate the biochemical and histopathological changes in the liver tissue high fat diet (HFD)-induced steatosis in rats.

**Materials and Methods:** In this study, 16 male Wistar-albino rats (160±30 g in weight) were used and divided into two groups: The normal fed diet group fed with a standard diet and the HFD group fed with a HFD for 10 weeks. At the end of the experiment, the liver sections and blood from the heart underwent biochemical and histological investigations. The sections obtained from the liver were examined by light and electron-microscopy and the sections stained immunohistochemically to determine the iNOS activity. The antioxidant activities in liver samples and the alanine aminotransferase (ALT), aspartate aminotransferase (AST), triglyceride (TG) levels in serum were measured.

**Results:** Because of light-microscopy and electron-microscopic investigations, histopathological changes caused the steatosis were observed in the HFD group. The histopathological damage observed in the liver was confirmed biochemically with the increase in the ALT, AST, and TG levels. While the malondialdehyde activity increased, the superoxide dismutase and catalase activities decreased in the HFD group. iNOS enzyme activity increased in the HFD group.

**Conclusion:** In this study, it was observed that steatosis developed in the liver tissue of rats fed with the HFD at 10 weeks and oxidative damage was triggered with the influence of inflammation and activation of the antioxidant defense system.

### Öz

**Amaç:** Karaciğer yağlanması kronik karaciğer hastalıklarının en yaygın sebeplerinden birisidir ve son yıllarda oldukça artmıştır. Bu çalışmada yüksek yağ içerikli diyetle (HFD) sıçanlarda oluşturulan yağlanma modelinin karaciğer dokularındaki etkilerinin yapısal ve biyokimyasal olarak araştırılması amaçlanmıştır.

**Gereç ve Yöntemler:** Çalışmada 16 adet Wistar albino cinsi erkek sıçan (160±30 g) kullanıldı. Sıçanlar rasgele iki gruba ayrıldı. Normal beslenen grup standart sıçan yemi ile ve HFD ile 10 hafta boyunca beslendi. Deney sonunda biyokimyasal ve yapısal incelemeler için karaciğer ve kalpten kan örnekleri alındı. Karaciğer

### Keywords

Liver steatosis, high fat diet, iNOS, rat

### Anahtar Kelimeler

Karaciğer yağlanması, yüksek yağ içerikli diyet, iNOS, sıçan

Received/Geliş Tarihi : 15.02.2021

Accepted/Kabul Tarihi : 15.11.2021

doi:10.4274/meandros.galenos.2021.32932

### Address for Correspondence/Yazışma Adresi:

Tuğba Çelik Samancı MD,  
Recep Tayyip Erdogan University Faculty  
of Medicine, Department of Histology and  
Embryology, Rize, Turkey  
Phone : +90 464 212 30 09  
E-mail : tugbacelik88@hotmail.com  
ORCID ID : orcid.org/0000-0002-5063-8104

©Meandros Medical and Dental Journal, Published by Galenos Publishing House.  
This is article distributed under the terms of the Creative Commons Attribution NonCommercial 4.0 International Licence (CC BY-NC 4.0).

dokusundan elde edilen kesitler ışık mikroskobu ve elektron mikroskobu ile incelendi ve iNOS enzim aktivitesini belirlemek amacıyla immünohistokimyasal olarak boyandı. Karaciğer dokularında malondialdehit (MDA), süperoksit dismutaz (SOD), CAT, glutatyon enzim aktiviteleri ve serum örneklerinde ALT, AST ve trigliserit (TG) seviyeleri ölçüldü.

**Bulgular:** Işık mikroskobu ve elektron mikroskopik incelemeler sonucunda HFD diyetle beslenen grupta yağlanmaya sebep olan yapısal değişiklikler gözlemlendi. HFD grupta gözlenen ALT, AST ve TG değerlerindeki artış ile karaciğerde gözlenen yapısal hasar biyokimyasal olarak da doğrulandı. HFD grupta MDA aktivitesi artarken SOD ve CAT aktivitelerinde düşüş gözlemlendi. HFD grupta iNOS enzim aktivitesi de anlamlı şekilde arttı.

**Sonuç:** Bu çalışmada 10 hafta boyunca yüksek yağ içerikli diyetle beslenen sıçanların karaciğer dokularında yağlanmanın geliştiği ve bu sürece inflamasyonunda etki etmesiyle birlikte oksidatif hasarın tetiklenip antioksidan savunma sisteminin devreye girdiği gözlemlendi.

## Introduction

Non-alcoholic fatty liver disease (NAFLD) is a pathology that results from excessive accumulation of fat in the liver independent of alcohol intake. NAFLD, with a prevalence of 25%, is one of the most common chronic diseases worldwide, including liver damage that can progress from simple steatosis to steatohepatitis, fibrosis and cirrhosis (1). Pathologically, NAFLD is characterized by excessive hepatic lipotoxicity, oxidative stress and inflammation. Hepatic steatosis, the earliest stage of NAFLD, occurs as a result of accumulation of lipid droplets in the cytoplasm of hepatocytes. The damage caused by lipid deposition increases the sensitivity of the liver to many factors such as pro-inflammatory cytokines, lipid peroxidation, mitochondrial dysfunction and oxidative stress. Oxidative stress triggers structural damage in the liver, causing changes in the antioxidant enzyme activities.

Various animal models have recently been used to understand the of NAFLD mechanism. In the development of NAFLD models, genetically modified animal models such as obese mice (ob/ob) and dyslipidemic mice were used, as well as rodent models fed with diets of different content (2-4). High fat diet (HFD) is the most common in diet induced NAFLD models and this model is the closest model to NAFLD formation in humans. However, the HFD content and duration of feeding with HFD cause differences in NAFLD progression. In studies investigating the effects of therapeutic substances in NAFLD, it is of great importance to monitor the stage from which the NAFLD regresses.

The objective of this study was to investigate the biochemical, immunohistochemical and histopathological as well as the ultrastructural changes that may occur in the liver of male wistar rats fed with a HFD containing 45% fat for 10 weeks.

## Materials and Methods

### Experimental Design

In our study, 16 Wistar albino male rats (weight  $160\pm 30$  g) were obtained from the Aydın Adnan Menderes University Laboratory of Experimental Animals (Aydın, Turkey). The research protocol was approved by Aydın Adnan Menderes University Animal Research Ethics Committee (no: 64583101/2014/058, date: 11.06.2014). During the experimental and adaptation processes, the rats were kept alive in optimum conditions (20-22 °C, humidity of 45-65% and 12-hour light, 12-hour dark). After the adaptation period, the rats were randomly divided into 2 groups (n=8). The control group [Normal fed diet (NFD) group] was fed with standard rat feed and the fattening group (HFD group) with a diet of high-fat content (HFD) for 10 weeks. During the experiment, the rats had unlimited access to drinking water and feed. The standard rat chow consumed by the control group was also obtained from Bil-Yem (Ankara, Turkey). The HFD diet, which contains fat (45%), carbohydrate (35%) and protein (20%), consumed by the HFD group, was prepared according to the content used in the experimental model created by Li et al. (5) in 2014. After the 10-week, the rats were sacrificed under anesthesia, the liver tissues were removed for biochemical and histopathological examinations, and blood samples were obtained from the heart tissues. The relative liver weights of rat were calculated using liver weights and final body weights [(liver weight/body weight) $\times 100$ ].

### Histopathological Examination

For the light microscopic examinations, the liver tissues were fixed in formalin (10%, 24 h). 5- $\mu$ m thick sections were taken from the paraffin-embedded tissues with a microtome. The liver sections were stained with Harris hematoxylin-eosin (H-E) (Merck,

Germany) for light microscobic investigation (BX50, Olympus, Japan) and photographed with a camera (DP21, Olympus, Japan).

For electron microscopic examinations, the liver tissues were fixed in glutaraldehyde (5%, 4h). Then, tissue samples washed with a Millonig phosphate buffer. Subsequently, the tissues detected with osmium tetroxide ( $\text{OsO}_4$ , 1%, 2h) were washed with the Millonig phosphate buffer. After the dehydration step, tissues treated with propylene oxide were embedded in araldite. Semi-thin sections obtained with ultramicrotome (Leica, Germany) were stained with toluidine blue stain. The thin liver sections were stained with lead citrate and uranyl acetate. The liver tissue samples were examined by electron microscopy (Zeiss E. M 10B). The fat content observed in hepatocytes with light microscopy and electron microscopy examinations was 0: (<5%), 1: (5% ~ 33%), 2: (34% ~ 66%) and 3: (>66%) relative to the reference (6).

#### Immunohistochemical Examination

For immunohistochemical examination, 5- $\mu\text{m}$  sections obtained from paraffin embedded tissues were taken on polylysine slides. After the deparaffinization process, it was passed through graded alcohol series. Ultra-V block (Lab Vision, TA125UB, USA) was applied to the liver tissues treated with hydrogen peroxide ( $\text{H}_2\text{O}_2$ ) to prevent background staining. Subsequently, 60-minutes incubation was performed using inducible nitric oxide synthase (iNOS) (NOS2, diluted 1: 500, Santa Cruz, Europe). The tissues were then treated with secondary antibody (TA-125-AF, Lab Vision Corporation, USA). AEC (TA125AF, Lab Vision Corporation, USA) and dropped on tissues and stained with Mayer's Hematoxylin to be examined. In the evaluation of the immunohistochemical staining, the immunoreactive prevalence (<25%=0.1, 26%-50%=0.4, 51%-75%=0.6, 76%-100%=0.9) and severity (none=0, very low=0.5, low=1, moderate=2, severe=3) were determined based on histoscore (Histoscore=prevalence x severity).

#### Biochemical Analysis

For biochemical analysis, blood samples were centrifuged for 15 min. The triglyceride (TG), alanine aminotransferase (ALT) and aspartate aminotransferase (AST) activities were analysed in serum samples. The liver samples obtained from the rats were homogenized in IKA Overhead Stirrer Homogenizer brand homogenizer (Yellow line) at 2000 rpm for 1 min. The homogenate was then centrifuged and the supernatant superoxide dismutase (SOD), malondialdehyde (MDA), glutathione peroxidase (GSH) and catalase (CAT) activities were measured (7-10).

#### Statistical Analysis

Statistical analysis of the data was performed using the SPSS 19.0 Software (IBM, USA),  $p < 0.05$  was considered significant. The normality of continuous variables was evaluated with the Kolmogorov-Smirnov test. The Student's t-test was used for the normally distributed data and the Mann-Whitney U test was used for the continuous variables that deviated from normality. Descriptive statistics were expressed as mean  $\pm$  standard deviation for the normally distributed continuous variables, and as median (25-75%) for the skewed parameters.

## Results

#### Rat Body Weights and Relative Liver Weights

During the experiment, the body weights of the rats were measured weekly and using the data obtained, the percentage change in the body weight of the rats was calculated [(final weight - initial weight)/final weight x 100]. Although there was an increase in the body weight in the HFD group, no significant difference was observed in the percentage of changes in body weight ( $p=0.674$ ) and the relative liver weight ( $p=0.782$ ) (Table 1).

#### Histopathological Analysis

As a result of examining the tissues stained with H-E and toluidine blue under the light microscope,

**Table 1. Representation of the rat body weights, relative liver weights and histoscore of iNOS immunoreactivity**

Variable	NFD group (n=8)	HFD group (n=8)	p-value
Percentage change in body weight (mean $\pm$ SD)	56.31 $\pm$ 4.27	65.68 $\pm$ 4.82	0.674
Relative Liver Weight (g/100 g) (mean $\pm$ SD)	3.69 $\pm$ 0.16	3.47 $\pm$ 0.17	0.782
iNOS immunoreactivity score median (25-75%)	0.30 (0.20-0.40)	0.41 (0.34-0.48)	0.021

NFD: Normal fed diet, HFD: High fat diet, SD: Standard deviation, iNOS: Inducible nitric oxide synthase

the hepatocytes and normal-appearing sinusoids were observed to be radially arranged around the central vein in the NFD group. Microvesicular and macrovesicular lipid drops were observed in the cytoplasm of hepatocytes around the central vein in the HFD group with H-E staining. Diffuse microvesicular and occasional macrovesicular lipid droplets were seen in the cytoplasm of hepatocytes in semi-thin sections stained with toluidine blue of liver samples obtained from rats belonging to the HFD group. Grade III steatosis was detected in the hepatocytes in liver tissues of rats in the HFD group as a result of examination of liver samples stained with H-E and toluidine blue under the light microscope and scoring of steatosis (Figure 1).

In electron microscopic examinations, the nuclei, and the nucleoli of the hepatic cells in the NFD group and the mitochondria and endoplasmic reticula were of normal size and shape. In electron microscopic examination of liver tissues of rats in the HFD group, macrovesicular and microvesicular lipid droplets were observed in hepatocytes with normal-appearing nuclei and nucleoli contents. In addition, degeneration of the mitochondria in the hepatocyte cytoplasm was observed in the cristae and most of the mitochondria were hypertrophied (Figure 1).

#### Immunohistochemical Examination

In the immunohistochemical staining performed with iNOS antibody to determine the iNOS enzyme activity, positivity was seen as granules (brown) in the cytoplasm of hepatocytes, particularly around the central vein in regions where the iNOS activity was positive (Figure 1). When the data obtained by scoring iNOS immunohistochemical staining were compared with the NFD group, a significant increase in the number of iNOS positive cells in the HFD group was observed ( $p=0.021$ ) (Table 1).

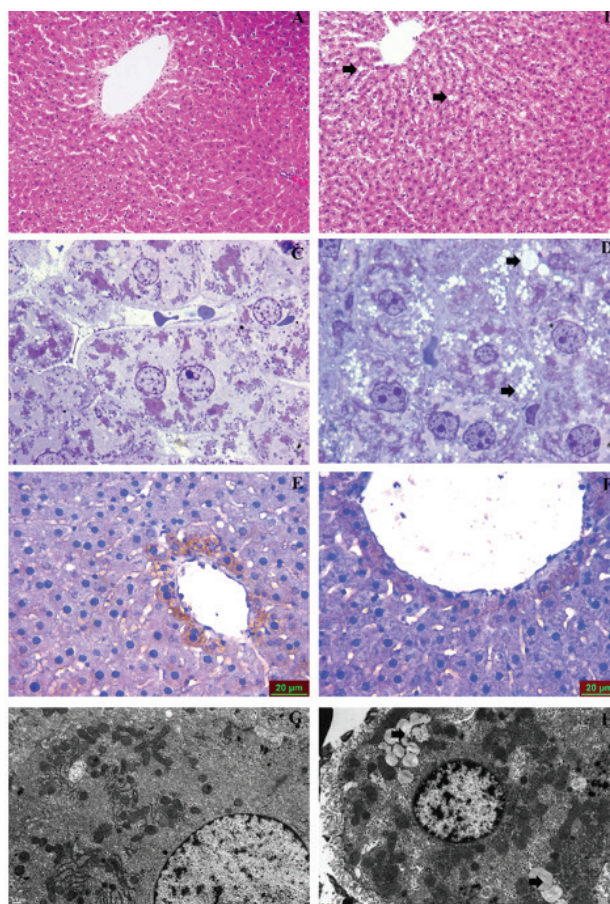
#### Biochemical Results

For biochemical analysis, serum ALT and AST activities increased in the HFD group compared to the NFD group ( $p=0.001$ ) (Table 2). In addition, the TG levels were significantly increased in the HFD group ( $p=0.001$ ) (Table 2). Compared to the NFD group, there was an increase in the MDA levels, which is an indicator of lipid peroxidation, in liver tissue samples in the HFD group ( $p=0.001$ ). Compared to the NFD group, there was a decrease in antioxidant enzyme levels measured in liver tissues in the HFD group,

SOD ( $p=0.001$ ) and CAT ( $p=0.005$ ) activities, while no significant difference was observed in the GSH levels ( $p=0.644$ ) (Table 2).

#### Discussion

NAFLD is a common cause of chronic liver disease, and its worldwide prevalence continues to increase. This situation triggers studies on the treatment and prevention of NAFLD (11). Experimental animal studies are very important to define the mechanisms that cause the progression of NAFLD to NASH. An



**Figure 1.** Photographic images of liver tissue from light and electron microscopic examination. A: NFD group hematoxylin-eosin staining 100x, B: HFD group Hematoxylin eosin staining 100x, C: NFD group toluidine blue staining 1000x, D: HFD group toluidine blue staining 1000x, E: NFD group iNOS immunohistochemical staining 400x, F: HFD group iNOS immunohistochemical staining 400x, G: NFD group electron microscopy image, H: HFD group Electron microscopy image. Arrows: Macro and microvesicular oil droplets  
NFD: Normal fed diet, HFD: High fed diet, iNOS: Inducible nitric oxide synthase

Variable	NFD group (n=8)	HFD group (n=8)	p-value
ALT (U/L) median (25-75%)	36.37 (35.10-37.20)	49.00 (42.02-54.50)	0.001
AST (U/L) median (25-75%)	105.16 (104.02-106.20)	127.01 (125.62-128.39)	0.001
TG (mg/dL) median (25-75%)	74.35 (69.41-83.37)	128.18 (118.85-138.42)	0.001
MDA (nmol/mg) median (25-75%)	28.09 (23.11-30.35)	55.51 (44.51-61.25)	0.001
SOD (U/mg) median (25-75%)	4.14 (3.70-4.72)	2.66 (2.50-2.71)	0.001
CAT (k/mg) median (25-75%)	12.42 (10.17-17.83)	7.81 (6.03-8.82)	0.005
GSH (mg/kg) (mean ± SD)	15.11±2.38	12.02±1.80	0.644

NFD: Normal fed diet, HFD: High fed diet, ALT: Alanine aminotransferase, AST: Aspartate aminotransferase, TG: Trygliceride, MDA: Malondialdehyde, SOD: Superoxide dismutaz, CAT: Catalase, GSH: Glutation peroxidase

ideal experimental model would be expected to reflect the etiology, progression, and pathology of human NAFLD (12). HFD is one of the most important models reflecting the real picture of human NAFLD. In the current study, the NAFLD model was created using HFD, which is considered as one of the main causes of NAFLD in humans. We conducted this study as a pilot of a study we designed for HFD-induced fatty liver therapy. Furthermore, we examined the biochemical and histopathological changes in the liver tissue of rats fed with a diet containing 45% fat for 10 weeks.

Experimental models of fatty liver have been created in various ways (12). In our study, fatty liver was created in rats using a diet with high-fat content, which is considered one of the main causes of fatty liver in humans. The fatty patterns vary depending on different lipid contents and different durations. The HFD diet we applied to rats in our study was prepared according to the study by Li et al. (5). The duration of 10 weeks is used in nutrition studies with HFD as the time in which fatty formation is formed and treatment is begun. Nutrition with HFD for 10 weeks is used in studies as the time in which active substances are used to create fat (13).

Although the mechanisms of NAFLD have not been understood yet, previous studies have indicated the most important causes of NAFLD as oxidative stress and increased lipid peroxidation (14). The increase in ROS as a result of feeding with HFD triggers lipid peroxidation in liver tissue by causing steatosis. Increased lipid peroxidation causes changes in antioxidant levels. Lipid peroxidation and oxidative stress due to increased Ros may cause deterioration in liver parenchyma and organelle structures.

As a result of the experiment, no significant increase in the percentage change in body weight was observed in the NFD and HFD groups, consistent with the study of Lieber et al. (15). There was no significant difference in the relative liver weights of the two groups, consistent with the literature (16,17).

Liver tissues stained with H-E were examined under a light microscope and we observed that the liver in the NFD group had a normal histological appearance. In the HFD group, microvesicular and macrovesicular lipid droplets were observed, which constitute the third degree of fat. Various researchers reported that feeding with HFD caused microvesicular and macrovesicular adiposity in rats in their histopathological examinations (18,19).

As a result of electron-microscopic examinations, it was observed that the NFD group had a normal histology, while in the HFD group, mitochondria were more hypertrophic, and deterioration occurred in the mitochondrial cristae. In the study carried out by Wang et al. (20), in the thin structure investigations performed on rats fed with HFD for 12 weeks, they demonstrated that HFD had caused mitochondrial damage comprising swelling in the mitochondrial matrix. Studies have shown that HFD causes histopathological damage in liver tissue, but that there may be differences in the degree of damage depending on the fat content and the duration of application (5).

ALT and AST, which we studied in the serum samples, are biochemical markers of liver damage. The TG content studied in serum samples provides information about the severity of fat accumulation. Consistent with previous studies, the increase in ALT,

AST, and TG content in the HFD group biochemically confirms the histopathological damage (21,22).

ROS, which occurs during the fatty liver process, increases the nitric oxide production with the development of inflammation in the liver and causes a progression in the damage to the tissues (23). When the iNOS enzyme activity was evaluated by immunohistochemical examination, there was an increase in enzyme activity in the HFD group. This increase is considered a marker of inflammation in liver tissue. The ROS increase caused by oxidative stress due to excessive lipid accumulation in liver tissue triggers the activation of the antioxidant defense system. In this context, the level of MDA, which is a lipid peroxidation marker, is an indicator of the increase in lipid peroxidation developing due to fat in the HFD group and is in parallel with the literature (24). While the SOD and CAT activities decreased in the HFD group, there was no difference in the GSH activity between the groups. Echeverría et al. (25) also reported that HFD diet administration caused a decrease in CAT and SOD activities in rats. This is the effect of oxidative stress on antioxidant enzyme activities, which is demonstrated by the increase in iNOS and MDA activities.

## Conclusion

In conclusion, this study shows that fatty liver disease induced by the HFD diet (containing 45% fat) causes histopathological and biochemical changes in liver tissue in rats. It was histopathologically and biochemically confirmed that the fatty model created for 10 weeks triggered oxidative stress in liver tissue. Furthermore, this study is a preliminary study for our study in which the treatment study of fatty liver is investigated and is a guide for studies to be conducted on the fatty model.

## Ethics

**Ethics Committee Approval:** The research protocol was approved by Aydın Adnan Menderes University Animal Research Ethics Committee (no: 64583101/2014/058, date: 11.06.2014).

**Informed Consent:** Since the materials used in this study do not related with any patient, informed patient approval was not required.

**Peer-review:** Externally and internally peer-reviewed.

## Authorship Contributions

Surgical and Medical Practices: T.Ç.S., A.G., Concept: T.Ç.S., A.G., Design: T.Ç.S., A.G., Data Collection or Processing: T.Ç.S., A.G., T.K., M.B., Y.K., S.P., Analysis or Interpretation: T.Ç.S., A.G., T.K., M.B., Y.K., S.P., Literature Search: T.Ç.S., A.G., Writing: T.Ç.S., A.G.

**Conflict of Interest:** No conflict of interest was declared by the authors.

**Financial Disclosure:** This research was supported by the Scientific Research Foundation of Aydın Adnan Menderes University (12023).

## References

- Adams LA, Angulo P, Lindor KD. Nonalcoholic fatty liver disease. *CMAJ* 2005; 172: 899-905.
- Koteish A, Diehl AM. Animal models of steatosis. *Semin Liver Dis* 2001; 21: 89-104.
- Iizuka K, Bruick RK, Liang G, Horton JD, Uyeda K. Deficiency of carbohydrate response element-binding protein (ChREBP) reduces lipogenesis as well as glycolysis. *Proc Natl Acad Sci U S A* 2004; 101: 7281-6.
- Kulinski A, Vance DE, Vance JE. A choline-deficient diet in mice inhibits neither the CDP-choline pathway for phosphatidylcholine synthesis in hepatocytes nor apolipoprotein B secretion. *J Biol Chem* 2004; 279: 23916-24.
- Li S, Liao X, Meng F, Wang Y, Sun Z, Guo F, et al. Therapeutic role of ursolic acid on ameliorating hepatic steatosis and improving metabolic disorders in high-fat diet-induced non-alcoholic fatty liver disease rats. *PLoS One* 2014; 9: e86724.
- Brunt EM, Janney CG, Di Bisceglie AM, Neuschwander-Tetri BA, Bacon BR. Nonalcoholic steatohepatitis: a proposal for grading and staging the histological lesions. *Am J Gastroenterol* 1999; 94: 2467-74.
- Sun Y, Oberley LW, Li Y. A simple method for clinical assay of superoxide dismutase. *Clin Chem* 1988; 34: 497-500.
- Aebi H. Catalase in vitro. *Methods Enzymol* 1984; 105: 121-6.
- Tietze F. Enzymic method for quantitative determination of nanogram amounts of total and oxidized glutathione: applications to mammalian blood and other tissues. *Anal Biochem* 1969; 27: 502-22.
- Ohkawa H, Ohishi N, Yagi K. Assay for lipid peroxides in animal tissues by thiobarbituric acid reaction. *Anal Biochem* 1979; 95: 351-8.
- Sumida Y, Yoneda M. Current and future pharmacological therapies for NAFLD/NASH. *J Gastroenterol* 2018; 53: 362-76.
- Jahn D, Kircher S, Hermanns HM, Geier A. Animal models of NAFLD from a hepatologist's point of view. *Biochim Biophys Acta Mol Basis Dis*. 2019;943-953.
- Chen XY, Cai CZ, Yu ML, Feng ZM, Zhang YW, Liu PH, et al. LB100 ameliorates nonalcoholic fatty liver disease via the AMPK/Sirt1 pathway. *World J Gastroenterol* 2019; 25: 6607-18.

14. Friedman SL, Neuschwander-Tetri BA, Rinella M, Sanyal AJ. Mechanisms of NAFLD development and therapeutic strategies. *Nat Med* 2018; 24: 908-22.
15. Lieber CS, Leo MA, Mak KM, Xu Y, Cao Q, Ren C, et al. Model of nonalcoholic steatohepatitis. *Am J Clin Nutr* 2004; 79: 502-9.
16. Wu Y, Wang C, Sun H, LeRoith D, Yakar S. High-efficient FLPo deleter mice in C57BL/6J background. *PLoS One* 2009; 4: e8054.
17. Park HJ, Lee JY, Chung MY, Park YK, Bower AM, Koo SI, et al. Green tea extract suppresses NFκB activation and inflammatory responses in diet-induced obese rats with nonalcoholic steatohepatitis. *J Nutr* 2012; 142: 57-63.
18. Chen X, Li L, Liu X, Luo R, Liao G, Li L, et al. Oleic acid protects saturated fatty acid mediated lipotoxicity in hepatocytes and rat of non-alcoholic steatohepatitis. *Life Sci* 2018; 203: 291-304.
19. Gårdebjer EM, Cuffe JSM, Ward LC, Steane S, Anderson ST, Dorey ES, et al. Effects of periconceptional maternal alcohol intake and a postnatal high-fat diet on obesity and liver disease in male and female rat offspring. *Am J Physiol Endocrinol Metab* 2018; 315: E694-704.
20. Wang Z, Li S, Wang R, Guo L, Xu D, Zhang T, et al. The protective effects of the β<sub>3</sub> adrenergic receptor agonist BRL37344 against liver steatosis and inflammation in a rat model of high-fat diet-induced nonalcoholic fatty liver disease (NAFLD). *Mol Med* 2020; 26: 54.
21. Xie X, Yan D, Li H, Zhu Q, Li J, Fang YP, et al. Enhancement of Adiponectin Ameliorates Nonalcoholic Fatty Liver Disease via Inhibition of FoxO1 in Type I Diabetic Rats. *J Diabetes Res* 2018; 2018: 6254340.
22. Yang JM, Sun Y, Wang M, Zhang XL, Zhang SJ, Gao YS, et al. Regulatory effect of a Chinese herbal medicine formula on non-alcoholic fatty liver disease. *World J Gastroenterol* 2019; 25: 5105-19.
23. Ding X, Jian T, Li J, Lv H, Tong B, Li J, et al. Chicoric Acid Ameliorates Nonalcoholic Fatty Liver Disease via the AMPK/Nrf2/NFκB Signaling Pathway and Restores Gut Microbiota in High-Fat-Diet-Fed Mice. *Oxid Med Cell Longev* 2020; 2020: 9734560.
24. Yi HW, Zhu XX, Huang XL, Lai YZ, Tang Y. Selenium-enriched *Bifidobacterium longum* protected alcohol and high fat diet induced hepatic injury in mice. *Chin J Nat Med* 2020; 18: 169-77.
25. Echeverría F, Valenzuela R, Bustamante A, Álvarez D, Ortiz M, Soto-Alarcon SA, et al. Attenuation of High-Fat Diet-Induced Rat Liver Oxidative Stress and Steatosis by Combined Hydroxytyrosol-(HT-) Eicosapentaenoic Acid Supplementation Mainly Relies on HT. *Oxid Med Cell Longev* 2018; 2018: 5109503.