

Neuroprotective effect of p-coumaric acid in rat model of embolic cerebral ischemia

Mustafa Guven^{1*}, Adem Bozkurt Aras¹, Tarik Akman¹, Halil Murat Sen¹, Adile Ozkan¹, Osman Salis², Ibrahim Sehitoglu³, Yildiray Kalkan⁴, Coskun Silan⁵, Mustafa Deniz⁶, Murat Cosar¹

¹ Department of Neurosurgery, Faculty of Medicine, Çanakkale Onsekiz Mart University, Çanakkale, Turkey

² Department of Medical Biochemistry, Faculty of Medicine, Ondokuz Mayıs University, Samsun, Turkey

³ Department of Pathology, Faculty of Medicine, Recep Tayyip Erdoğan University, Rize, Turkey

⁴ Department of Histology & Embryology, Faculty of Medicine, Recep Tayyip Erdoğan University, Rize, Turkey

⁵ Department of Pharmacology, Faculty of Medicine, Çanakkale Onsekiz Mart University, Çanakkale, Turkey

⁶ Department of Physiology, Faculty of Medicine, Çanakkale Onsekiz Mart University, Çanakkale, Turkey

ARTICLE INFO

Article type:

Original article

Article history:

Received: Jul 7, 2014

Accepted: Aug 22, 2014

Keywords:

Apoptosis

Coumaric acids

Ischemia

Neuroprotective agents

Nuclear respiratory factor 1

Rats

ABSTRACT

Objective(s): Stroke poses a crucial risk for mortality and morbidity. Our study aimed to investigate the effect of p-coumaric acid on focal cerebral ischemia in rats.

Material and Methods: Rats were randomly divided into four groups, namely Group I (control rats), Group II (ischemia rats), Group III (6 hr ischemia + p-coumaric acid rats) and Group IV (24 hr ischemia + p-coumaric acid rats). Cerebral ischemia was induced via intraluminal monofilament occlusion model. In all groups, the brain was removed after the procedure and rats were sacrificed. Malondialdehyde, superoxide dismutase and nuclear respiratory factor-1 were measured in the ischemic hemisphere. The histopathological changes were observed in the right hemisphere within the samples. Functional assessment was performed for neurological deficit scores.

Results: Following the treatment, biochemical factors changed significantly. Histopathologically, it was shown that p-coumaric acid decreased the oxidative damage. The neurological deficit scores of p-coumaric acid-treated rats were significantly improved after cerebral ischemia.

Conclusion: Our results showed that p-coumaric acid is a neuroprotective agent on account of its strong anti-oxidant and anti-apoptotic features. Moreover, p-coumaric acid decreased the focal ischemia. Extra effort should be made to introduce p-coumaric acid as a promising therapeutic agent to be utilized for treatment of human cerebral ischemia in the future.

► Please cite this paper as:

Guven M, Bozkurt Aras A, Akman T, Murat Sen H, Ozkan A, Salis O, Sehitoglu I, Kalkan Y, Silan C, Deniz M, Cosar M. Neuroprotective effect of p-coumaric acid in rat model of embolic cerebral ischemia. Iran J Basic Med Sci 2015; 18:356-363.

Introduction

Cerebral ischemia is still a serious clinical problem leading to permanent neurological deficit and complications. Primary injury (contusion, edema and pressure) inevitably causes cell death and creates permanent damage. If ischemia continues after primary injury, it causes edema, an increase in capillary permeability and secondary damage depending on the inflammation both within and near the damaged region (1). At this stage, glutamate-induced excitotoxicity, oxidative stress, protein synthesis inhibition, demyelination, apoptosis, autophagy, etc. occur (1, 2). Although there have been many studies focusing on various neuroprotective agents in order to prevent the secondary damage, today we still do not have any effective treatment for cerebral ischemia.

Polyphenolic compounds are described as chemopreventive agents. Following the discovery of

biological activities of these compounds in past years, studies on flavonoids, a type of polyphenolic compound, have become more important. Simonyi *et al* showed the neuroprotective effects of polyphenols in cerebral ischemic lesions (2). P-coumaric acid (CA), a polyphenolic compound, is synthesized from cinnamic acid by P450-dependent 4-cinnamic acid hydroxylase enzyme (3). The main sources of CA are the fruits (e.g. apple and pear), the vegetables (e.g. beans, soy bean, potato and tomato), the drinks (e.g. tea, coffee, wine and beer) and chocolate (4).

In vitro and *in vivo* researches have shown that CA inhibits platelet aggregation (5). Studies have demonstrated that CA supports free radicals scavenging as a strong inhibitor of oxidation of the low density lipoprotein (LDL). Also, CA decreases the production of malonilaldehyde (MDA) which reduces potential hazards to biological membranes thereby

*Corresponding author: Mustafa Guven. Department of Neurosurgery, Çanakkale Onsekiz Mart University, Faculty of Medicine, Çanakkale, Turkey. Tel: +90 505 6418969; Fax: +90 286 2635956; email: drmustafaguvan@comu.edu.tr

decreasing atherosclerosis (6). In another study that was done in rats, CA has shown a protective effect against the recurrent inflammation of the small intestine induced by dextran sodium sulfate (7). Moreover, it has also been shown that CA ameliorates osteoporosis due to estrogen deficiency in rats (8). Because of its strong tyrosine kinase inhibitory activity, CA inhibits melanin synthesis; therefore it is also considered as a kind of antimelanogenic agent (9). Many studies concerning CA have shown its chemoprotective (10), neuroprotective (11), cardioprotective (12-15), anti-microbial (16), anti-cancer (3, 17, 18), anti-ulcer (19) and anti-inflammatory (20) effects. No study was found in a review of the English medical literature showing neuroprotective effect of CA on cerebral ischemia. In our study, the anti-oxidants and anti-apoptotic effects of CA have been demonstrated. Therefore, CA may provide a novel and promising therapeutic strategy for treatment of human cerebral ischemia.

Materials and Methods

Animals

The rats were obtained from Çanakkale Onsekiz Mart University Experimental Research Center. Sprague-Dawley male rats (300±25 g, 8-12 week old) were used in this experiment. Rats were kept for a week before the start of the experiment to adapt to the environment. This study was conducted in Çanakkale Onsekiz Mart University Experimental Research Center. A standard pellet diet (Bil-Yem Ltd., Ankara, Turkey) and tap water were provided *ad libitum*. Rats were provided with a photo-periodic medium at 21±2 °C, with the humidity of 60±5% and white fluorescent tube lighting (8:00 AM 8:00 PM light, 8:00 PM 8:00 AM dark). Experiments were carried out with the permission of Çanakkale Onsekiz Mart University Animal Ethics Committee in accordance with the "Guide for the Care and Use of Laboratory animals (8th edition, 2011)" (Number: 2012/08-13).

Reagents

p-Coumaric acid (≥98% purity by HPLC) was obtained from Sigma-Aldrich (St Louis, MO, USA). The drug was dispersed with ethanol and the final concentration in ethanol was 20%. Modified Lowry Protein Assay Kit was obtained from Thermo Scientific Inc. (Waltham, MA, USA). SOD Assay Kit was obtained from Cayman Chemical Company (Ann Arbor, Michigan, USA). Rat Malondialdehyde ELISA Kit and Rat Nuclear Respiratory Factor-1 ELISA Kit were obtained from Hangzhou Eastbiopharm Co. Ltd. (Hangzhou, China). Anti-Caspase-3 antibody and Anti-Caspase-9 antibody were obtained from Abcam plc. (Cambridge, UK).

Dosage

The dosage was determined as 100 mg/kg body weight based on preliminary studies with various

doses (50, 75, 100 mg) to reveal the biological effects of CA (3, 5-7, 9, 11, 12, 16, 17, 20).

Experimental design

Rats were randomly divided into four groups (N=8).

Group I: Control rats received intraperitoneal vehicle alone (20% ethanol) (CN).

Group II: Rats received a single dose 1 ml intraperitoneal vehicle (20% ethanol) following middle cerebral artery occlusion (MCAO) (sham operated group).

Group III: Intraperitoneal CA (100 mg/kg b wt) was administered to rats. Animals were sacrificed 6 hr after MCAO application (MCAO+CA6).

Group IV: Intraperitoneal CA (100 mg/kg b wt) was administered to rats. Animals were sacrificed 24 hr after MCAO application (MCAO+CA24).

Surgical Procedure

Anesthesia for all groups was achieved with intraperitoneal administration of xylazine (5 mg/kg) (Bayer, Istanbul, Turkey) and ketamine hydrochloride (50 mg/kg) (Ketalar, Eczacıbaşı, Istanbul, Turkey) under spontaneous breathing of ambient air. A Biopac MP36 (BIOPAC Systems, Inc. Goleta, CA, USA) device was used as the monitor. Mean arterial pulse was 375 per min during surgery. Body temperature was monitored with a rectal probe and was adjusted to 37.1 to 37.4 °C with a heating pad. Temperature of the temporal muscle was recorded to measure the brain heat and the temperature was also adjusted to 36.2 to 37.0 °C using a heating lamp. Rats were operated on an operating table under sterile conditions. In the supine position paramedian incision from the right side of the neck was performed to skin and subcutaneous tissue. Bifurcation of right common carotid artery was explored. Focal cerebral ischemia was achieved with middle cerebral artery occlusion (MCAO) using the intraluminal filament technique as described earlier (21). In order to create MCAO, monofilament nylon suture with silicone-coated tip (Ethicon Inc., Somerville, New Jersey, USA) (external diameter 0.28 mm) was propagated by means of a small incision from the carotid bifurcation to 16-18 mm distal of the internal carotid artery. Rats received intraperitoneal CA 100 mg/kg, 5 min after the MCAO application. All of the rats showed weakness in the left side (rotating around own axes and/or drop to the left) when they woke from anesthesia. Thus, it was verified that ischemia induces neurological deficits. Before rats were sacrificed, the whole brain had been removed by craniotomy. As soon as the brain was removed, the intraluminal monofilament suture was occluded in the MCA. Brain tissue was rinsed with 0.9% saline solution, dried with filter paper and put into ice. Half of the right hemisphere was stored at -80 °C within labeled sterilized plastic bags for tissue biochemistry examinations. The other half of the right hemisphere was fixed in 4% paraformaldehyde solution for

Table 1. The activity of superoxide dismutase, level of malondialdehyde and nuclear respiratory factor-1 in brain tissue of rats

Groups	SOD	MDA	NRF-1
	(U/mg protein)	(nmol/ml/mg protein)	(nmol/ml/mg protein)
I - CN	7,15 ± 1,07	0,40 ± 0,12	2,68 ± 0,66
II - MCAO (Sham operated)	1,78 ± 0,41 ^a	2,00 ± 0,31 ^a	0,41 ± 0,15 ^a
III - MCAO+CA6	4,06 ± 0,82 ^{b,d}	1,48 ± 0,20 ^{b,d}	1,33 ± 0,28 ^{b,d}
IV - MCAO+CA24	4,86 ± 0,86 ^{c,e}	1,35 ± 0,25 ^{c,e}	1,36 ± 0,29 ^{c,e}

a,b,c $P < 0.05$ compared to CN groups. d,e $P < 0.05$; compared to MCAO (sham operated) groups.

Data represent means±SD; CN: Control; MCAO: Middle Cerebral Artery Occlusion; CA: Coumaric Acid

histopathological and immunohistochemical analysis.

Biochemical estimations

Tissue specimens were pulverized with liquid nitrogen. Then, they were homogenized with 1 ml of cold PBS on ice for 30 sec at 20,000 rpm. The resultant homogenates were centrifuged for 10 min at 4 °C and 10,000 rpm. Supernatants were moved to another tube. All samples were stored at -80 °C until examination. The samples were brought to 2-8 °C on the day of study.

Measuring the Levels of Protein, SOD, MDA and NRF1

The protein content of the brain tissue was measured using the method of Lowry *et al* (22). Results are shown as mg/ml.

Tissue SOD activity was determined by nitroblue tetrazolium (NBT) method which was described by Sun *et al* and modified by Durak *et al* (23). A Shimadzu spectrophotometer (Shimadzu Corp, Kyoto, Japan) was used for SOD assay. In this method, NBT is reduced to blue formazan with superoxide. SOD activity is reported as U/mg protein.

MDA levels were analyzed for lipid peroxidation products (24). MDA levels were estimated by ELISA technique. MDA results are presented as nmol/ml/mg protein.

NRF-1 target genes control cell adhesion, cell spreading, migration, proliferation and apoptosis. NRF1 levels were determined by ELISA technique. NRF1 results are reported as nmol/ml/mg protein.

Histopathology

Tissues were washed under running water for about 6-8 hr after 24 hr fixation. Next, they were passed through ethanol-xylene series and embedded into paraffin after conducting automatic tissue tracing (Citadel 2000, Thermo Fisher Scientific Shandon, England). Thickness of tissue slices were 4-6 µm for routine Hematoxylin-Eosin (HE) and Luxol Fast Blue (LFB) staining, and 3-4 µm for immunohistochemical staining.

Slices that were prepared for immunohistochemical staining were put in xylene for 20 min. Then, they were kept in 3% H₂O₂ for 10 min after being passed through alcohol series (70-99%). Slices were heated in citrate buffer solution 4 times at 700-800 watt for 5 to 10 min (each time) after being rinsed with Phosphate Buffered

Saline (PBS). Slices were kept in a secondary blocking agent for 20 min. Each specimen was incubated for 60-75 min in different dilutions (1/200-1/250) of primary antibody. Diaminobenzidine (DAB) solution was used as the chromogen. Contrast coloring was stained with Mayers hematoxylin. PBS was used for negative controls. Samples were covered with suitable covering material and photos of samples were taken. In terms of the percentage values of immunopositive reactions in every area, the results of the immunohistochemical staining were categorized into 4 categories namely light (+), moderate (++) , strong (+++) and very strong (++++). For each specimen, 15 different regions of hematoxylin staining were identified. Each area was 1200 micrometer square and cell density was determined by counting the neuronal cells.

Functional assessment

The degree of functional deficit was scored using the five-point Bederson's scale (25): 0, no deficit; 1, mild forelimb weakness; 2, severe forelimb weakness, consistently turns to side of deficit when lifted by tail; 3, compulsory circling; 4, unconscious; and 5, dead. Neurological status was scored at 0, 6 and 24 hr after ischemia. Functional assessment was done by a neurologist who was not involved in giving medication or performing the experiments in rats.

Statistics

SPSS 19.0 (SPSS Inc., Chicago, IL, USA) was used for statistical analysis. The comparisons among four groups were made by one-way analysis of variance (ANOVA) followed by *Bonferroni post-hoc* tests. Histopathological findings were assessed by Kruskal Wallis test. Statistical significance was accepted as $P < 0.05$.

Results

Biochemical analysis

SOD, MDA and NRF-1 concentrations

When CN group was compared to the other groups, SOD values showed a statistically significant decrease ($P < 0.05$). It was observed that the MCAO group showed a significant decrease in SOD values compared to the other groups ($P < 0.05$). There was a statistically significant increase in SOD values in MCAO+CA6 and MCAO+CA24 groups compared to the MCAO group

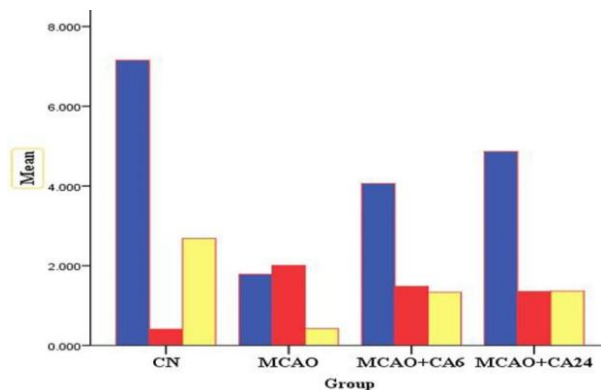


Figure 1. Superoxide dismutase, malonaldehyde and nuclear respiratory factor-1 levels in rats brain tissues

($P < 0.05$). Considering SOD values, no significant difference was observed between MCAO+CA6 and MCAO+CA24 groups ($P > 0.05$) (Table 1).

MDA values revealed statistically significant increases in the CN group in comparison with other groups ($P < 0.05$). The MCAO group showed statistically significant increase in MDA values in comparison with all other groups ($P < 0.05$). Also, a significant decrease in MDA values occurred in the MCAO+CA6 and MCAO+CA24 groups compared to the MCAO group ($P < 0.05$). Regarding MDA values, there was no significant difference between MCAO+CA6 and MCAO+CA24 groups ($P > 0.05$) (Table 1).

A statistically significant decrease was observed in NRF-1 levels in the CN group compared to the other groups ($P < 0.05$). A statistically significant decrease was seen in the MCAO group compared to all other groups ($P < 0.05$). CA treatment further increased the protein level of NRF-1 at each time point and the levels significantly increased at 6 hr and 24 hr ($P < 0.005$) after stroke. Therefore, NRF-1 significantly increased in control ($P < 0.005$) and at 24

hr ($P < 0.005$) in CA treated group, compared to the respective time points in the MCAO group. No significant difference was observed between MCAO+CA6 and MCAO+CA24 groups ($P > 0.05$). Therefore, activities were either brought back to normal level or significantly improved by CA compared to non-CA-treated brain tissue (Figure 1).

Histopathological findings

Findings of Hematoxylin&Eosin and Luxol Fast Blue Staining

Histopathological examination of brain tissues in the CN group showed cells and tissues with normal histological morphology following both Hematoxylin&Eosin and Luxol Fast Blue staining (Figure 2).

In the MCAO group, some cells shriveled up, and appeared to have vacuolization and edema areas within and around the neuroglial area. It was observed that microglial cells were located in red neurons and the vicinity of vacuolar regions were stained intensely (Figure 2). Pyramidal neurons of the MCAO group in luxol-fast staining showed rather basophilic characteristics with respect to the control group. Nuclei of neurons in external pyramidal lamina appeared to be large and were stained slightly basophilic. A remarkable increase in the number of red neurons was observed (Figure 2).

Following Hematoxylin-Eosin staining, an increase in neuronal damage and nuclear chromatin density was observed in MCAO+CA6 and MCAO+CA24 groups as compared to the CN group. Damaged neuronal appearance with karyorrhexis was detected in red neurons with intense acidophilic neuronal cytoplasm and pyknotic structure. Cells which appeared to look like red neurons were found in large quantities on the outer granular layer of MCAO groups.

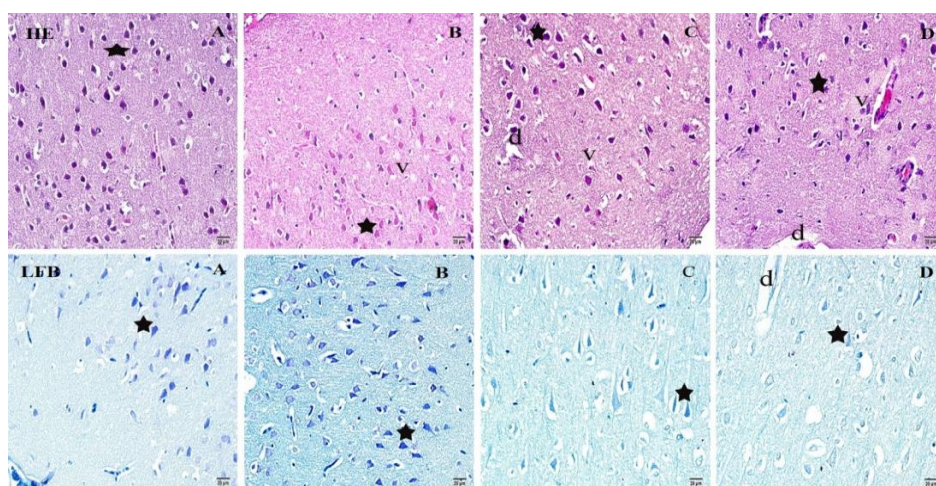


Figure 2. Representative photomicrographs showing neurons stained with Hematoxylin&Eosin and Luxol Fast Blue in the ischemic brain area of rats after middle cerebral artery occlusion. (A) Control group; (B) MCAO group; (C) MCAO+CA6 group, sacrificed after 6 hr; (D) MCAO+CA24 group, sacrificed after 24 hr. Red neurons are shown as stars. Vascular dilatations (d) shown. Scale Bars=20 µm

Table 2. Degree and frequencies of histopathological findings obtained through Hematoxylin-Eosin and Luxol Fast Blue staining

Groups	Red neuron		Vacuolization		Neuronal degeneration		Edema	
	Median±SD	%	Median±SD	%	Median±SD	%	Median±SD	%
I	2,0 ± 0,35	60	1,0 ± 0,35	5	0,0 ± 0,52	2	1,0 ± 0,35	5
II	4,0 ± 0,46 ^a	70	4,0 ± 0,46 ^a	80	3,0 ± 0,74 ^a	70	3,0 ± 0,53 ^a	80
III	3,0 ± 0,89 ^{b,d}	65	3,0 ± 0,74 ^{b,d}	35	2,0 ± 0,71 ^{b,d}	35	2,0 ± 0,46 ^{b,d}	45
IV	2,0 ± 0,88 ^{c,e,g}	25	3,0 ± 0,70 ^{c,e,g}	25	1,0 ± 0,35 ^{c,e,f}	15	1,0 ± 0,35 ^{c,e,f}	25

^{a,b,c} $P < 0,05$ compared to CN groups; ^{d,e} $P < 0,05$; compared to MCAO (sham treated) groups; ^f $P < 0,05$ compared to MCAO+CA6 group
^g $P > 0,05$ compared to MCAO+CA6 group

Vacuolar regions were observed around the cells in the MCAO+CA6 group. Amounts of vacuolar regions were lessened in quantity compared to the MCAO group. The number of red neurons observed in MCAO+CA24 group was less than that of the MCAO group (Figure 2).

The degree and frequency of histopathologic findings obtained through HE and LFB staining are summarized in Table 2.

Immunohistochemical staining signs

Anti-caspase-3 immunoperoxidase

A ring-like dense immunoreactivity was observed in nuclei of neurons and the periphery of nuclei within the MCAO groups after immunoperoxidase staining with caspase-3. It was found that caspase-3 activity increased in cortex and sub-cortex regions. Another finding was that caspase-3 immunopositivity occurred extensively in the ischemic zone. The presence of intensive apoptotic nucleated cells was determined. Observed necrotic cell morphologies and vacuolization in cells in the ischemic region affected the positivity. There was an increase in the number of microglial cell clusters around damaged regions in the ischemia group. In contrast, the MCAO+CA6 group revealed little caspase-3 immunopositivity compared to the MCAO group and the immunopositivity was the same as the CN group. Less immunoreactivity of caspase-3 was also found in the MCAO+CA24 group compared to the MCAO+CA6 group (Figure 3).

Anti-Caspase-9 immunoperoxidase

Caspase-9 positivity on neuronal degeneration occurring in the MCAO group was denser compared to the CN group. Caspase-9 immunopositivity in the MCAO+CA6 and MCAO+CA24 groups was less than that of the MCAO group. It was determined that immunopositivity of caspase-9 in the MCAO+CA6 group was similar to the MCAO+CA24 group.

Caspase-9 staining around large cortical neurons showed both ring form and intranuclear granular shape. The most sensitive region was found to be the

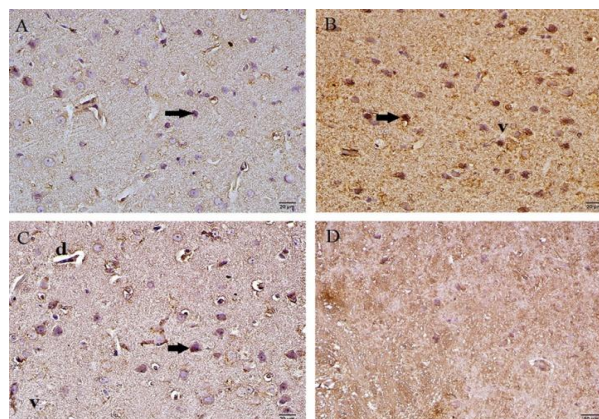


Figure 3. Effects of p-coumaric acid on caspase-3 expression in the ischemic brain site detected by immunohistochemical methods at 6 hr and 24 hr after experimental ischemia. The representative example of caspase-3 immunohistochemical images in ischemic brain section from the control group (A), sham-operated group (B), MCAO+CA6 group (100 mg/kg, IP) (C) and MCAO+CA24 group (100 mg/kg, IP) (D). Caspase-3 expression in neurons (black arrows), vascular dilatations (d) and vacuolization (v) shown. Scale Bars=20 μ m

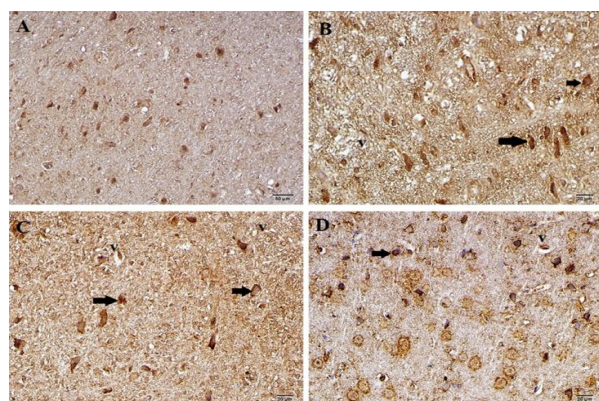


Figure 4. Effects of p-coumaric acid on caspase-9 expression in the ischemic brain site detected by immunohistochemical methods at 6 hr and 24 hr after experimental ischemia. The representative example of caspase-9 immunohistochemical images (black arrows) in ischemic brain section in control group (A), sham-operated group (B), MCAO+CA6 group (C) and MCAO+CA24 group (D). Caspase-9 expression in neurons (black arrows) and vacuolization (v) shown. Scale Bars=20 μ m

Table 3. The degree of anti-caspase-3 and anti-caspase-9 immunoreactivity

Groups	Anti-caspase-3 median±SD	Anti-caspase-9 median±SD
CN	2,0 ± 0,64	2,0 ± 0,53
MCAO	4,00±0,74 ^a	4,00±0,46 ^a
MCAO+CA6	2,00±0,53 ^{b,d}	3,00±0,89 ^{b,d}
MCAO+CA24	1,00±0,64 ^{c,e,f}	3,00±0,83 ^{c,e,g}

^{a, b, c} $P < 0,05$ compared to CN groups

^{d, e} $P < 0,05$; compared to MCAO (sham treated) groups

^f $P < 0,05$ compared to MCAO+CA6 group

^g $P > 0,05$ compared to MCAO+CA6 group

CN: Control; MCAO: Middle Cerebral Artery Occlusion;

CA: Coumaric Acid

CA1 region in the hippocampus in ischemia groups, whereas apoptosis was less dense in the CA3 and dentate gyrus regions (Figure 4). Immunoreactivity degrees of caspase-3 and caspase-9 are summarized in Table 3.

Percentage values of positive reactions in tissues on immunohistochemical staining are shown in Table 4.

Functional assessment

After cerebral ischemia, animals exhibited a variety of neurological deficits. Our results revealed that CA could improve neurological deficit scores. The neurological scores were significantly increased ($P < 0.05$) 6 and 24 hr after ischemia compared to the sham-operated rats. Treatment of CA significantly improved the neurological deficit when compared to sham-operated rats. Moreover, the neurological scores of the 24 hr group were significantly better than those of the 6 hr group ($P < 0.05$). No score was found in the CN rats or in the hemisphere contralateral to the ischemic side.

Discussion

Currently, high doses of steroids are used in the early stages of cerebral ischemia treatment in order to minimize the cerebral damage, mortality and morbidity. Experimental studies on many neuroprotective agents are still ongoing. In some studies, a relationship between reduction in neurotoxicity and anti-oxidant intake within the diet has been observed (11). The present study was carried out to investigate the possible neuroprotective effect of p-coumaric acid against cerebral ischemia in rats concerning biochemical, histopathological and functional assessment findings.

There are many studies to date on CA as an antioxidant taken with diet. Abdel-Wahap *et al* (12)

reported that CA acts as a cardioprotective agent against oxidative stress. Janicke *et al* (18), Ferguson *et al* (17) and Kong *et al* (3) reported the anti-cancer activity of CA. Roy (13), Prince (15) and Prasanna *et al* (14) reported that CA has a protective effect on infarct size occurring in cardiotoxicity and lessens apoptosis. Pragasam *et al* (20) also showed the anti-inflammatory effect of CA. An experiment in mice neuron culture by Vauzour *et al* (11) showed neuroprotective effect against 5-S-cysteinyl-dopamine-induced neurotoxicity. However, so far no study has investigated the neuroprotectivity of CA on cerebral ischemia.

SOD, MDA, and NRF-1 values were used to evaluate biochemical results of CA treatment in ischemic tissue after cerebral injury. It is known that ischemia elevates the formation of reactive oxygen species (ROS) in brain tissue (26). ROS is produced as a result of metabolic reactions. ROS may cause cellular damage through oxidation of membrane lipids, essential cellular proteins and DNA (27).

MDA is the ultimate product of lipid peroxidation and it is one of the most sensitive indicators of lipid peroxidation (28). As long as fatty acids, O₂ and metal catalysts (Fe⁺², Cu⁺) are present in the medium, lipid peroxidation results in the formation of new free radicals. For this reason, the reperfusion period is quite amenable to lipid peroxidation (29). Since lipid peroxidation may improve membrane permeability, it may cause a decrease in membrane-bounded Na⁺-K⁺ ATPase enzyme activity. As a result, K⁺ and Mg²⁺ concentrations have vital importance for denatured and attenuated protein synthesis.

Increased lipid peroxidation may result in the release of mitochondrial matrix enzymes and lysosomal proteolytic enzymes in the cytoplasm. In this situation, intracellular proteolysis and cellular destruction increase (29). As a consequence, the immune system including SOD as an antioxidant enzyme involves a wide range of cellular activity to protect neuronal cells from ROS-induced cell death (30). SOD detoxifies O₂ to H₂O₂ which is then scavenged by peroxisomal catalase. In brief, H₂O₂ can not be easily scavenged during ischemia due to the lower activity of SOD (30).

When a large amount of free oxygen radicals produced during ischemia exceeds the immune capacity of the organism, they react with polyunsaturated fatty acids-main components of cell

Table 4. Percentage values of immunoreactions as a result of caspase-3 and caspase-9 staining

Groups	Anti-caspase-3 (%)				Anti-caspase-9 (%)			
	+	++	+++	++++	+	++	+++	++++
CN	15	65	5	5	10	65	5	20
MCAO	5	5	20	70	5	15	5	75
MCAO+CA6	10	55	20	15	10	15	50	25
MCAO+CA24	60	25	5	10	10	15	55	10

CN: Control; MCAO: Middle cerebral artery occlusion; CA: Coumaric acid

membranes- to induce lipid peroxidation (31). Although MDA is not a specific indicator of fatty acid oxidation, it exists in correlation with the degree of lipid peroxidation. An increase in MDA concentration indicates the degree of lipid peroxidation depending on oxidative stress in tissue (28). In our study, tissue MDA levels increased significantly in the MCAO group compared to the CN group. In the MCAO+CA6 and MCAO+CA24 groups, MDA levels decreased significantly compared to the MCAO group. SOD activity decreased significantly in the MCAO group compared to the CN group. In addition to these data, the significant increase in SOD activity in the MCAO+CA6 and MCAO+CA24 groups compared to the MCAO group points to the possible neuroprotective and anti-oxidant effects of CA in ischemic brain tissue.

Nuclear respiratory factor-1 (NRF-1) activates some key gene expressions regulating cell growth and development as well as nuclear genes coding for respiration proteins. It activates heme biosynthesis and mitochondrial DNA transcription and replication. NRF-1 responds to redox signaling pathways through post-translational modifications and through its specific interaction with transcriptional co-activators (32). Due to CA's unique feature of ameliorating mitochondrial function via improving mitochondrial biogenesis, it might be a good strategy against many stress situations including neurodegenerative diseases. In our case study, embolism of the human brain was simulated one to one. Therefore, reperfusion was not made via withdrawal of the intraluminal filament. Thus, NRF-1 values were decreased in the MCAO group. NRF-1 values in the CA-treated ischemic groups were increased significantly. In accordance with the literature, NRF-1 values in our study display a proportional increase with duration of reperfusion in the ischemia-reperfusion groups, and it increases further when neuroprotective agents are administered (32, 33). Our study shows that CA ameliorates the suppression of ischemia-induced respiratory complex activities and it increases mitochondrial oxidative phosphorylation. These results show that the utilitarian effect of CA might arise from the increase of mitochondrial protein synthesis and biogenesis.

The neuroprotective effect of CA arises from its capacity to activate both ERK and Akt signaling pathways (34). These pathways lead to inhibition of mitochondrial-associated pro-apoptotic protein, apoptosis signal-regulating kinase 1 (ASK1) and caspase activity (34). In accordance with the literature review, our study showed that caspase-3 and caspase-9 immunoreactivity markedly decreased in CA-treated groups. Our study demonstrates the anti-oxidant and neuroprotective effect of CA through modulation of the apoptosis mechanism.

Conclusion

As a result, our findings illustrate the neuroprotective effect of CA on cerebral ischemia. However, studies at molecular level, which are underway, are required to unravel the exact mechanism of CA against cerebral ischemia.

Acknowledgment

This work was funded by authors. The authors declare that they have no conflict of interest. All the co-authors have seen and approved the final version of the manuscript.

References

1. Thong-asa W, Tilokskulchai K. Neuronal damage of the dorsal hippocampus induced by long-term right common carotid artery occlusion in rats. *Iran J Basic Med Sci* 2014; 17:220-226.
2. Simonyi A, Wang Q, Miller RL, Yusof M, Shelat PB, Sun AY, *et al.* Polyphenols in cerebral ischemia: novel targets for neuroprotection. *Mol Neurobiol* 2005; 31:135-147.
3. Kong CS, Jeong CH, Choi JS, Kim KJ, Jeong JW. Antiangiogenic effects of p-coumaric acid in human endothelial cells. *Phytother Res* 2013; 27:317-323.
4. King A, Young G. Characteristics and occurrence of phenolic phytochemicals. *J Am Diet Assoc* 1999; 99:213-218.
5. Luceri C, Giannini L, Lodovici M, Antonucci E, Abbate R, Masini E, *et al.* p-Coumaric acid, a common dietary phenol, inhibits platelet activity *in vitro* and *in vivo*. *Br J Nutr* 2007; 97:458-463.
6. Zang LY, Cosma G, Gardner H, Shi X, Castranova V, Vallyathan V. Effect of antioxidant protection by p-coumaric acid on low-density lipoprotein cholesterol oxidation. *Am J Physiol Cell Physiol* 2000; 279:954-960.
7. Luceri C, Guglielmi F, Lodovici M, Giannini L, Messerini L, Dolara P. Plant phenolic 4-coumaric acid protects against intestinal inflammation in rats. *Scand J Gastroenterol* 2004; 39:1128-1133.
8. Folwarczna J, Zych M, Burczyk J, Trzeciak H, Trzeciak HI. Effects of natural phenolic acids on the skeletal system of ovariectomized rats. *Planta Med* 2009; 75:1567-1572.
9. Seo YK, Kim SJ, Boo YC, Baek JH, Lee SH, Koh JS. Effects of p-coumaric acid on erythema and pigmentation of human skin exposed to ultraviolet radiation. *Clin Exp Dermatol* 2011; 36:260-266.
10. Hudson EA, Dinh PA, Kokubun T, Simmonds MS, Gescher A. Characterization of potentially chemopreventive phenols in extracts of brown rice that inhibit the growth of human breast and colon cancer cells. *Cancer Epidemiol Biomarkers Prev* 2000; 9:1163-1170.
11. Vauzour D, Corona G, Spencer JP. Caffeic acid, tyrosol and p-coumaric acid are potent inhibitors of 5-S-cysteinyl-dopamine induced neurotoxicity. *Arch Biochem Biophys* 2010; 501:106-111.
12. Abdel-Wahab MH, El-Mahdy MA, Abd-Ellah MF, Helal GK, Khalifa F, Hamada FM. Influence of p-coumaric acid on doxorubicin-induced oxidative stress in rat's heart. *Pharmacol Res* 2003; 48:461-

- 465.
13. Jyoti Roy A, Stanely Mainzen Prince P. Preventive effects of p-coumaric acid on lysosomal dysfunction and myocardial infarct size in experimentally induced myocardial infarction. *Eur J Pharmacol* 2013; 699:33-39.
 14. Prasanna N, Krishnan DN, Rasool M. Sodium arsenite-induced cardiotoxicity in rats: protective role of p-coumaric acid, a common dietary polyphenol. *Toxicol Mech Methods* 2013; 23:255-262.
 15. Stanely Mainzen Prince P, Roy AJ. p-Coumaric acid attenuates apoptosis in isoproterenol-induced myocardial infarcted rats by inhibiting oxidative stress. *Int J Cardiol* 2013; 168:3259-3266.
 16. Cho JY, Moon JH, Seong KY, Park KH. Antimicrobial activity of 4-hydroxybenzoic acid and trans 4-hydroxycinnamic acid isolated and identified from rice hull. *Biosci Biotechnol Biochem* 1998; 62:2273-2276.
 17. Ferguson LR, Zhu ST, Harris PJ. Antioxidant and antigenotoxic effects of plant cell wall hydroxycinnamic acids in cultured HT-29 cells. *Mol Nutr Food Res* 2005; 49:585-593.
 18. Janicke B, Onning G, Oredsson SM. Differential effects of ferulic acid and p-coumaric acid on S phase distribution and length of S phase in the human colonic cell line Caco-2. *J Agric Food Chem* 2005; 53:6658-6665.
 19. Barros MP, Lemos M, Maistro EL, Leite MF, Sousa JP, Bastos JK, *et al.* Evaluation of antiulcer activity of the main phenolic acids found in Brazilian Green Propolis. *J Ethnopharmacol* 2008; 120:372-377.
 20. Pragasam SJ, Murunikara V, Sabina EP, Rasool M. Ameliorative effect of p-coumaric acid, a common dietary phenol, on adjuvant-induced arthritis in rats. *Rheumatol Int* 2013; 33:325-334.
 21. Hata R, Mies G, Wiessner C, Fritze K, Hesselbarth D, Brinker G, *et al.* A reproducible model of middle cerebral artery occlusion in mice: hemodynamic, biochemical, and magnetic resonance imaging. *J Cereb Blood Flow Metab* 1998; 18:367-375.
 22. Lowry OH, Rosebrough NJ, Farr AL, Randall RJ. Protein measurement with the Folin phenol reagent. *J Biol Chem* 1951; 193:265-275.
 23. Durak I, Yurtarslan Z, Canbolat O, Akyol O. A methodological approach to superoxide dismutase (SOD) activity assay based on inhibition of nitroblue tetrazolium (NBT) reduction. *Clin Chim Acta* 1993; 214:103-104.
 24. Buege JA, Aust SD. Microsomal lipid peroxidation. *Methods Enzymol* 1978; 52:302-310.
 25. Bederson JB, Pitts LH, Tsuji M, Nishimura MC, Davis RL, Bartkowski H. Rat middle cerebral artery occlusion: evaluation of the model and development of a neurologic examination. *Stroke* 1986; 17:472-476.
 26. Yaman M, Eser O, Cosar M, Bas O, Sahin O, Mollaoglu H, *et al.* Oral administration of avocado soybean unsaponifiables (ASU) reduces ischemic damage in the rat hippocampus. *Arch Med Res* 2007; 38:489-494.
 27. Lancelot E, Callebert J, Revaud ML, Boulu RG, Plotkine M. Detection of hydroxyl radicals in rat striatum during transient focal cerebral ischemia: possible implication in tissue damage. *Neurosci Lett* 1995; 197:85-88.
 28. Gutteridge JM. Lipid peroxidation and antioxidants as biomarkers of tissue damage. *Clin Chem* 1995; 41:1819-1828.
 29. White BC, Grossman LI, Krause GS. Brain injury by global ischemia and reperfusion: a theoretical perspective on membrane damage and repair. *Neurology* 1993; 43:1656-1665.
 30. Bosca L, Hortelano S. Mechanisms of nitric oxide-dependent apoptosis: involvement of mitochondrial mediators. *Cell Signal* 1999; 11:239-244.
 31. Braughler JM, Hall ED. Central nervous system trauma and stroke. I. Biochemical considerations for oxygen radical formation and lipid peroxidation. *Free Radic Biol Med* 1989; 6:289-301.
 32. Gutsaeva DR, Carraway MS, Suliman HB, Demchenko IT, Shitara H, Yonekawa H, *et al.* Transient hypoxia stimulates mitochondrial biogenesis in brain subcortex by a neuronal nitric oxide synthase-dependent mechanism. *J Neurosci* 2008; 28:2015-2024.
 33. Kumari S, Anderson L, Farmer S, Mehta SL, Li PA. Hyperglycemia alters mitochondrial fission and fusion proteins in mice subjected to cerebral ischemia and reperfusion. *Transl Stroke Res* 2012; 3:296-304.
 34. Vauzour D, Vafeiadou K, Rice-Evans C, Williams RJ, Spencer JP. Activation of pro-survival Akt and ERK1/2 signalling pathways underlie the anti-apoptotic effects of flavanones in cortical neurons. *J Neurochem* 2007; 103:1355-1367.