

## Original Article

# Effect of infliximab on acute hepatic ischemia/reperfusion injury in rats

Ahmet Fikret Yucel<sup>1</sup>, Ahmet Pergel<sup>1</sup>, Ibrahim Aydin<sup>1</sup>, Hasan Alacam<sup>2</sup>, Ilhan Karabicak<sup>3</sup>, Tugrul Kesicioglu<sup>4</sup>, Levent Tumkaya<sup>5</sup>, Yildiray Kalkan<sup>5</sup>, Ender Ozer<sup>1</sup>, Zakir Arslan<sup>6</sup>, Ibrahim Sehitoglu<sup>7</sup>, Dursun Ali Sahin<sup>1</sup>

<sup>1</sup>Department of Surgery, School of Medicine, Recep Tayyip Erdogan University, Rize, Turkey; <sup>2</sup>Department of Biochemistry, School of Medicine, Hacettepe University, Ankara, Turkey; <sup>3</sup>Department of Surgery, School of Medicine, Ondokuz Mayıs University, Samsun, Turkey; <sup>4</sup>Department of Surgery, School of Medicine, Giresun University, Giresun, Turkey; <sup>5</sup>Department of Histology and Embryology, School of Medicine, Recep Tayyip Erdogan University, Rize, Turkey; <sup>6</sup>Clinics of Anesthesiology, Erzurum Training and Research Hospital, Erzurum, Turkey; <sup>7</sup>Department of Pathology, School of Medicine, Recep Tayyip Erdogan University, Rize, Turkey

Received March 14, 2015; Accepted October 24, 2015; Epub November 15, 2015; Published November 30, 2015

**Abstract:** This study aimed to investigate the hepatoprotective and antioxidant effects of infliximab (IFX) against liver ischemia/reperfusion (I/R) injury in rats. A total of 30 male Wistar albino rats were divided into three groups: sham, I/R, and I/R+IFX. IFX was given at a dose of 3 mg/kg for three days before I/R. Rat livers were subjected to 60 min of ischemia followed by 90 h of reperfusion. Aspartate aminotransferase (AST), alanine aminotransferase (ALT), TNF- $\alpha$ , malondialdehyde (MDA), and glutathione peroxidase (GSH-Px) levels were measured in the serum. The liver was removed to evaluate the histopathologic changes. The I/R group had a significant increase in AST, ALT, MDA, and TNF- $\alpha$  levels, and a decrease in GSH-Px activity compared with the sham group. The use of IFX significantly reduced the ALT, AST, MDA and TNF- $\alpha$  levels and significantly increased GSH-Px activity. IFX attenuated the histopathologic changes. IFX has a protective effect on liver I/R injury. This liver protective effect may be related to antioxidant and anti-TNF- $\alpha$  effects. We propose that, for the relief of liver injury subsequent to transplantation, liver resection, trauma, and shock, tentative treatments can be incorporated with IFX, which is already approved for clinical use.

**Keywords:** Liver, ischemia/reperfusion injury, infliximab, oxidative stress, rat

## Introduction

Ischemia/reperfusion (I/R) injury can develop after many life-threatening conditions and diseases, such as liver resection, organ transplantation, and hemorrhagic shock, and it greatly contributes to tissue and organ dysfunction [1]. Liver injury secondary to warm ischemia and reperfusion is a significant clinical condition. It plays a role in the pathogenesis of many clinical conditions, such as trauma, thermal injury, hypovolemic and endotoxic shock, reconstructive vascular surgery, liver transplantation, and liver resections [2-4]. Liver injury development after the initiation of reperfusion is a consequence of interactions among complex mechanisms. The early phase of liver injury (i.e., first 2 h of reperfusion) is characterized by the activation of macrophages and Kupffer cells (KC) in the liver. Activated KC induces liver damage by

stimulating reactive oxygen species (ROS) and many inflammatory cytokines, such as TNF- $\alpha$  and interleukins [5, 6]. TNF- $\alpha$  and interleukin-1(IL-1) are the two cytokines that have a prominent role in hepatic I/R injury [7, 8]. TNF- $\alpha$  induces the local production of the chemokine epithelial neutrophil activating protein-78 [9] and stimulates the production of superoxide radicals in KC [10]. IL-1 induces TNF- $\alpha$  synthesis in KC and increases the formation of ROS regulated by neutrophils [11, 12].

In the early period involving the first 5 min of reperfusion initiation, the levels of TNF- $\alpha$  and IL-1 increase [13]. The roles of these two cytokines in liver I/R injury are confirmed by experimental studies. As evidence of reduced neutrophil infiltration and parenchymal injury, studies show that the severity of the reperfusion injury

## Infliximab on acute hepatic injury

is attenuated by the neutralization of the responsible cytokines with antisera, monoclonal antibodies, and receptor antagonists [11, 12].

Infliximab (IFX) is a chimeric immunoglobulin G1 (IgG1) antibody composed of mouse variable fragments and human heavy chains [14]. Various *in vitro* experiments showed that the IFX inhibits functional TNF- $\alpha$  activity in human fibroblasts, endothelial cells, neutrophils, lymphocytes and epithelial cells [15]. IFX is used in the treatment of various rheumatological, gastrointestinal, dermatological, and chronic ocular diseases. It relieves inflammation and scavenges ROS [16, 17]. This study aims to investigate the protective activity of IFX in liver injury induced by using an I/R model in rats. Our results indicate that IFX contributes to the healing of liver injury secondary to I/R.

### Material and methods

#### Animals

Male albino Wistar rats (275 g-375 g) were used. All the animals were kept under optimum conditions (22 $\pm$ 2°C, 50%-55% humidity, 12/12 dark-light cycle) and were fed ad libitum with standard pellet diet and water. All experimental protocols were approved by Recep Tayyip Erdogan University's Ethic Committee for Animal Research.

#### Experimental groups

A total of 30 male Wistar albino rats were divided into three groups: sham, ischemia-reperfusion (I/R), and I/R+IFX (I/R+IFX); each group was composed of 10 rats. Animals were pre-treated with IFX intravenously (dose of 3 mg/kg body weight) for three days before I/R, as described for the I/R group.

#### Hepatic I/R technique

Animal feeding was stopped 12 h prior to the start of the hepatic I/R procedure, and all the rats received only water. The rats were anesthetized with ketamine (50 mg/kg) and xylazine (5 mg/kg) intraperitoneally, and their temperature was regulated by a lamp light bulb during the test. The rats were placed in a supine position and secured in the dissection tray. The abdominal region was shaved and cleaned with

antiseptic solution. Partial hepatic ischemia was induced by performing a midline laparotomy, exposing the liver hilum. Portal structures to the left and median lobes were clamped with a microvascular clip, yielding about 70% of the hepatic ischemia. These procedures prevent splanchnic congestion by allowing flow through the remaining liver [18]. The abdominal wall was closed during hepatic ischemia that lasted for 60 min. Sham-operated rats underwent the same procedure without clamping the pedicle of the liver lobes. At the end of the reperfusion period (90 min), the animals were terminated by exsanguination through cardiac puncture and blood collection. A sample of liver tissue was taken from the left lobe and stored in formalin for histopathology.

#### Measurement of liver enzymes, TNF- $\alpha$ , malondialdehyde (MDA), and glutathione peroxidase (GSH-Px)

TNF- $\alpha$  was measured in serum specimens using enzyme-amplified sensitivity immunoassay method according to the manufacturer's protocol (Diasource ImmunoAssays SA, Louvain-la-Neuve, Belgium). Measurement was conducted on a microplate reader (Sunrise-Basic, Tecan, Grödig, Austria). Results were expressed as pg/mL.

The amount of MDA was determined using the method of Draper et al [19]. After trichloroacetic acid was pipetted into the serum specimens, the specimens were incubated at 90°C for 15 min and centrifuged at 4°C at 3000 g for 20 min. Thiobarbituric acid was added to the supernatant obtained. Absorbance of the specimens was determined at 532 nm. MDA values were calculated based on the extinction coefficient ( $1.56 \times 10^5 \text{ cm}^{-1} \text{ M}^{-1}$ ) of the TBA-MDA complex. Results were reported as  $\mu\text{mol/dl}$ .

GSH-Px activity was measured according to the method of Paglia et al [20]. GSH-Px catalyzed the oxidation of reduced glutathione to oxidized glutathione. In the next stage, formed glutathione was reduced to reduced glutathione in the presence of glutathione reductase and NADPH. Therefore, serum was pipetted into the medium containing reduced glutathione, NADPH, and glutathione reductase and incubated at room temperature for 30 min. In the next stage, hydrogen peroxide was added; a decrease in absorbance was recorded. GSH-Px activity was

## Infliximab on acute hepatic injury

calculated by recording the absorbance in 1 min. Results were reported as U/dl.

Serum aspartate aminotransferase (AST) and alanine aminotransferase (ALT) activities were measured through spectrophotometric method using an autoanalyzer (P800 Modular Analytics P, Roche Diagnostic Ltd., West Sussex, UK).

### *Histopathology*

The liver specimens were fixed in 10% neutral formaldehyde for 24 h, washed under running water for 8 h, and embedded in liquid paraffin by rinsing out with ethanol-xylene series using an automated tissue follow-up system (Citadel 2000, Thermo Fisher Scientific, Shandon, England). Tissues were cut in 5  $\mu\text{m}$  thickness using a rotary microtome (RM2255, Leica, Wetzlar, Germany) for hematoxylin-eosin (H&E) staining and in 3  $\mu\text{m}$  thickness for immunohistochemical (IHC) staining.

### *Immunohistochemistry*

Tissue sections of 3  $\mu\text{m}$  thick were collected on glass slides. For histopathological evaluation, sections were stained with H&E and examined with a digital camera (DP72, Olympus, Tokyo, Japan) attached to a light microscope (BX51, Olympus, Tokyo, Japan). Calcineurin (CN) immunoreactivity was assessed using streptavidin-biotin peroxidase method. EnVision™ FLEX DAB chromogen (DM827, DAKO, Glostrup, Denmark) and EnVision™ FLEX Substrate Buffer (DM823, DAKO) were used to detect peroxidase activity. The liver tissue specimens were deparaffinized with xylene for streptavidin-biotin peroxidase method and then rehydrated in graded ethanol series. Slices were incubated in 3%  $\text{H}_2\text{O}_2$  to block endogenous peroxidase activity and to block nonspecific binding sites of antibodies in normal bovine serum. Each slide was allowed to stand for 75 min in different dilutions of primary antibody (liver arginase 1  $\mu\text{g}/\text{mL}$ ) before being stained by anti-liver arginase antibody (Cod: ab91279, Abcam plc, Cambridge, UK). The primary antibody [Purified Mouse Anti-Calcineurin (Clone: 29-Calcineurin, 1/200 dilution ratio, BD Biosciences, San Diego, California, USA)] and a biotinylated secondary antibody (Universal LSAB Kit-K0690, DAKO) were used. Sections were incubated with primary antibodies used for 60 min at room temperature (22°C-24°C)

and then incubated with streptavidin-horseradish peroxidase (Universal LSAB Kit-K0690, DAKO) for 30 min. Antibody binding sites were stained with 3,3-diaminobenzidine (DAB) and then washed with phosphate buffer solution with saline. Nuclei were stained with EnVision™ FLEX Hematoxylin (Code K8018, DAKO), dehydrated with ethanol series, and cleared with xylene. The treated sections were then mounted with Entellan (Code107960, Merck, Darmstadt, Germany) and examined under a light microscope. Tissue injury in the liver was evaluated using a light microscope according to the criteria described by Chiu et al. and scored between 0 and 5 [21]. Immunohistochemical staining preparations were categorized into four items according to the tissues percentage of immunopositive reaction areas as mild (+), moderate (++) , severe (+++) , and very severe (++++). All histologists slides were reviewed by two histologist and one pathologist who were blinded for the rat groups.

### *Statistical methods*

Data were analyzed using the SPSS program (SPSS for Windows, v. 12.0, IBM, Chicago, IL, USA). AST, ALT, MDA, TNF, and GSH-Px values were expressed as mean  $\pm$  SD and analyzed using one-way ANOVA with a least significant difference ( $P < 0.05$ ). Multiple comparison tests (Post Hoc Tukey HSD parametric tests) were used to identify the significant differences among groups with the  $P$  value set to  $< 0.015$ . The assessment of the histopathological status and intensity of IHC reactions was expressed as the median  $\pm$  SD. Kruskal-Wallis test was used for inter-group analysis ( $P < 0.05$ ) and Mann-Whitney-U test for the pairwise comparison of groups ( $P < 0.016$ ).

## **Results**

### *AST, ALT, TNF- $\alpha$ , MDA, and GSH-Px levels*

The I/R group had a significant increase in AST, ALT, MDA ( $P < 0.01$ ), and TNF- $\alpha$  ( $P < 0.05$ ) levels and a decrease in GSH-Px ( $P < 0.01$ ) level compared with the sham group. The intravenous administration of IFX significantly reduced the ALT, AST, MDA ( $P < 0.01$ ), and TNF- $\alpha$  ( $P < 0.05$ ) levels. The administration of IFX also significantly increased the GSH-Px activity ( $P < 0.05$ ).

## Infliximab on acute hepatic injury

**Table 1.** Biochemical findings in all study groups (n=10)

	Study Groups		
	Sham	I/R	I/R+IFX
	Mean ± SD	Mean ± SD	Mean ± SD
ALT (U/L)	65.28±9.62	2357.14±446.68 <sup>b</sup>	254.28±105.99 <sup>d</sup>
AST (U/L)	68.14±21.09	433.57±123.51 <sup>b</sup>	143.0±24.87 <sup>d</sup>
TNF-α (pg/mL)	30.26±8.28	107.72±48.34 <sup>a</sup>	41.64±13.85 <sup>c</sup>
MDA (μmol/dL)	1.23±0.08	1.78±0.08 <sup>b</sup>	1.31±0.04 <sup>d</sup>
GSH-Px (nmol/min/mL)	85.32±47.38	28.93±13.39 <sup>b</sup>	66.51±21.05 <sup>c</sup>

Data are presented as mean ± SD. Sham: control group, I/R: ischemia and reperfusion group, I/R+IFX: ischemia and reperfusion group treated with IFX, IFX: infliximab, ALT: alanine aminotransferase, AST: aspartate aminotransferase, MDA: malondialdehyde, TNF-α: tumor necrosis factor alpha, GSH-Px: glutathione peroxidase. <sup>a</sup>P<0.05 compared with the control (sham) group. <sup>b</sup>P<0.01 compared with the control (sham) group. <sup>c</sup>P<0.05 compared with the I/R and the I/R+IFX groups. <sup>d</sup>P<0.01 compared with the I/R and the I/R+IFX groups.

**Table 2.** Histopathologic and immunohistochemistry results

	Sham	IR	IR+IFX
	Median ± SD	Median ± SD	Median ± SD
Sinusoidal dilatation	1.00±0.42 <sup>a</sup>	4.00±0.48 <sup>a</sup>	2.00±0.47
Hepatocyte vacuolization	0.00±0.48 <sup>b</sup>	4.00±0.48 <sup>b</sup>	2.00±0.31 <sup>b</sup>
Hepatocyte degeneration	1.00±0.48 <sup>c</sup>	3.00±0.47 <sup>c</sup>	2.00±0.42
Swelling of endothelial cells	1.00±0.48 <sup>d</sup>	3.00±0.47 <sup>d,e</sup>	2.00±0.48 <sup>e</sup>
CN immunopositivity	3.00±0.42 <sup>f</sup>	1.00±0.42 <sup>f</sup>	2.00±0.31
LA immunopositivity	2.00±0.42	1.00±0.70 <sup>g</sup>	2.00±0.63 <sup>h</sup>

Data are presented median ± SD. Sham: control group, I/R: ischemia and reperfusion group, I/R+IFX: ischemia and reperfusion group treated with IFX, IFX: infliximab, CN: Calcineurin, LA: Liver arginase. <sup>a</sup>P<0.016 compared with the control (sham) group and IR group. <sup>b</sup>P<0.016 compared with the control (sham) group, IR group and IR+IFX group. <sup>c</sup>P<0.016 compared with the control (sham) group and IR group. <sup>d</sup>P<0.016 compared with the control (sham) group and IR group, the control (sham) group and IR+IFX group, IR group and IR+IFX group. <sup>e</sup>P<0.016 compared with the IR group and IR+IFX group. <sup>f</sup>P<0.016 compared with the control (sham) group and IR group. <sup>g</sup>P<0.05 compared with the control (sham) group and IR group. <sup>h</sup>P<0.05 compared with the IR group and IR+IFX group.

The biochemical findings in all study groups are presented **Table 1**.

### *Histopathologic and immunohistochemistry results*

I/R injury caused serious morphological changes in the liver as revealed by the histopathological investigations. These histopathological changes involved sinusoidal dilatation, vacuolization and degeneration of hepatocytes, endothelial swelling, and neutrophil infiltration. Eosinophil granulocytes and neutrophil granulocyte infiltrations were detected around the portal area. There were necrotic cells and shedding related to hepatocyte degenerations in both around central vein and portal regions. Ex-

amination between the first and second groups: a statistically significant differences were found in terms of sinusoidal dilatation, hepatocyte degeneration (P<0.016). Examination between the first and second, between the first and third, and between second and third groups: a statistically significant difference was found in terms of swelling of endothelial cells (P<0.016). The histopathological examination ischemic reperfusion and IFX applied group revealed lower histopathological changes than ischemic reperfusion group. The histopathologic results are presented in **Table 2** and **Figure 1**.

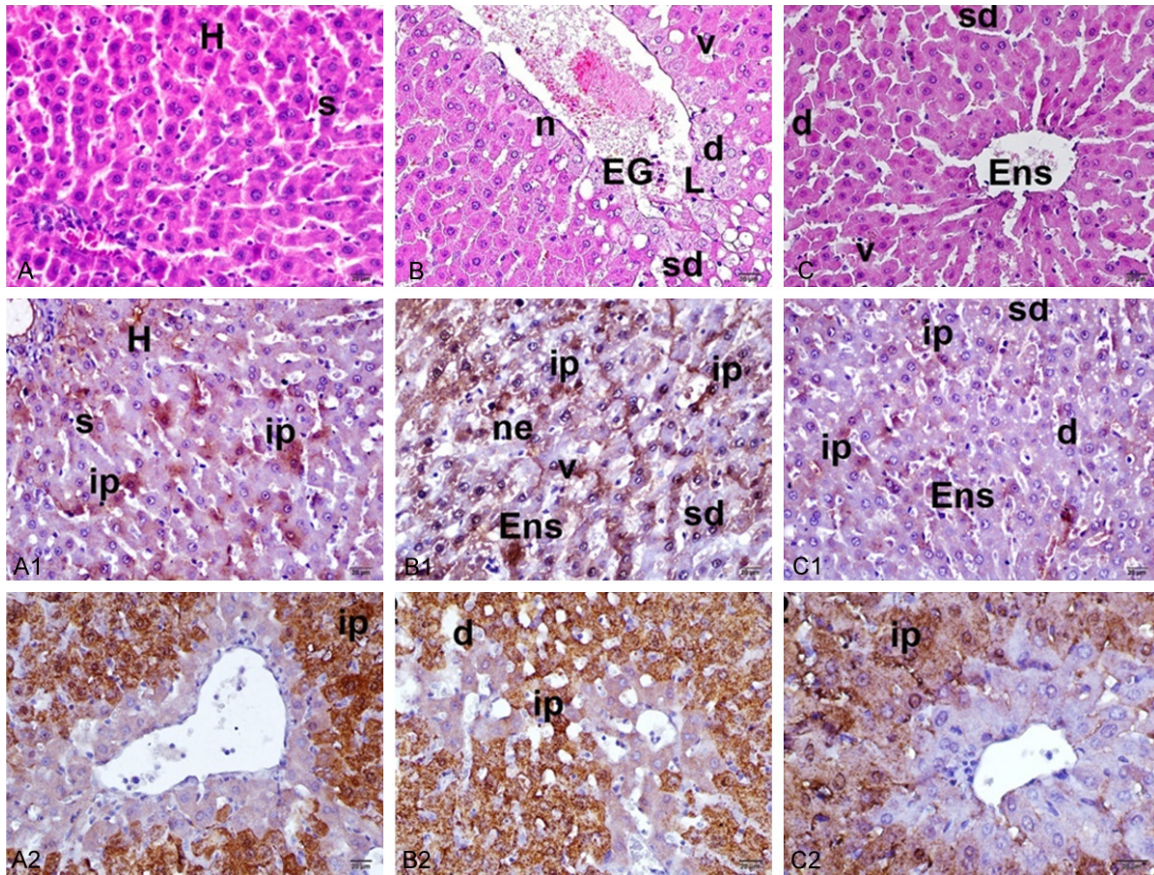
Examination between the first and second groups: a statistically significant differences were found in CN immunopositivity (P<0.016) and liver arginase immunopositivity (P<0.05). Examination between the second and third groups: a statistically significant difference was found in liver arginase immunopositivity (P<0.05).

There was increased anti liver arginase reactivity all treated hepatic I/R with IFX groups compared to untreated groups (P<0.05). Immunohistochemistry results are presented in **Table 2** and **Figure 1**.

### **Discussion**

ROS plays an important role in I/R pathophysiology. The body's antioxidant defense system constitutes a complex mechanism that normally keeps the ROS production under control. However, excess ROS production leads to the development of oxidant stress. Hepatocytes are relatively resistant to ROS because of their inherently high levels of antioxidant enzymes, such as GSH-Px, superoxide dismutase, and





**Figure 1.** Histopathologic and immunohistochemical examination of the rat liver. (A, A1, A2) Control group, (B, B1, B2) ischemia/reperfusion (I/R) group, (C, C1, C2) I/R+ IFX group, H: normal hepatocyte, s: sinusoid, EG: eosinophil granulocyte, sd: sinusoidal dilatation, V: vacuolization, d: degeneration, L: lymphocyte, ed: edema, n: necrotic area, ip: immune-positive cells, ne: necrosis, Ens: endothelial swelling. (A-C: H&E stain,  $\times 40$ , A1-C1: Anti-Calceurin antibody, Immunoperoxidase stain,  $\times 40$ . A2-C2: Anti-liver arginase antibody, Immunoperoxidase stain,  $\times 40$ ).

catalase. MDA is a side product of lipid peroxidation and a sensitive parameter of lipid peroxidation [1]. When reperfusion is applied after temporary liver ischemia, the antioxidant enzyme levels rapidly decrease and ROS begins to damage various cellular molecules. The consequences of oxidative stress contribute to the pathogenesis of liver injury. Liver I/R injury continues to be an unavoidable clinical problem in liver surgery, transplantation, shock, and trauma [22, 23]. ALT and AST levels are generally measured as indirect biochemical indices of liver injury [24]. Similarly, various studies show that liver I/R is associated with an autocatalytic lipid peroxidation process that damages cellular membranes [25, 26]. ROS is produced during I/R, and it contributes to further pathological complications. Lipid peroxidation and protein oxidation, which cause cell membrane injury, and irreversible protein modifications are responsible for the pathogenesis of I/R injury [27-29].

In this study, the levels of the sensitive oxidative stress indicator MDA were elevated and those of the antioxidative enzyme indicator GSH-Px were depleted in the I/R group. MDA levels decreased and GSH-Px levels increased in the I/R+IFX group.

The I/R injury induced by the Pringle maneuver in rat liver can be prevented with prior IFX treatment. This protective effectiveness in association with oxidative stress and inflammatory responses is demonstrated through the reduction of ALT and AST levels. In this study, ALT and AST levels considerably elevated after I/R most likely because of cell membrane damage. Compared with those in the I/R group, TNF- $\alpha$  and MDA levels markedly decreased in the I/R+IFX group. Moreover, I/R injury caused serious morphological changes in the liver as revealed by the histopathological investigations. These histopathological changes involved

sinusoidal dilatation, vacuolization and degeneration of hepatocytes, endothelial swelling, and neutrophil infiltration. A comparison between I/R and I/R+IFX groups showed a conspicuous improvement of these changes in the IFX-treated group. These improvements are considered to be associated with antioxidant effects following the IFX-blockage of TNF- $\alpha$ , which triggers cellular injury by various mechanisms. I/R is a predominantly acute inflammatory response induced by leukocyte chemotaxis to the damaged parenchymal region and by the subsequent triggering of inflammatory mediators; endogenous mechanisms work to limit these inflammatory responses [30]. Ischemia-activated KC constituted the major source of vasoactive oxygen species in the early stage following reperfusion. KC also caused the production of cytokines, such as TNF- $\alpha$  and IL-1 [31-33]. Inflammatory cytokines such as TNF- $\alpha$ , which has an important role in the hepatic I/R pathophysiology, are also released from the apoptotic and necrotic hepatocytes and vascular endothelial cells [9, 34]. TNF- $\alpha$  is the major inducer of adhesion molecules on the endothelial cell surface and the trigger of neutrophil-attracting CXC chemokines [35, 36]. These two processes lead to sinusoidal endothelial cell death and more damage to the hepatocytes. This study found that the TNF- $\alpha$ -induced noxious effects that cause I/R injury are evidently attenuated in the IFX-applied group. These positive effects are linked to the liver tissue protective effects of IFX.

CN is an important protein phosphatase that contributes to the regulation of immune T and B cells modified by TNF- $\alpha$  and that activates the T lymphocytes that cause the further production of other cytokines [37]. In a previous study, attenuations in the CN immunopositivities are detected in certain tissues following apoptotic or necrotic cell death, and distinct increases in CN immunopositivities occurred during cellular regeneration [38, 39]. In the evaluation of the findings of the current study in terms of CN levels, CN immunopositivity was more prominent in the I/R+IFX group than in the I/R group. This effect was assumed to be linked to the positive effects of IFX-mediated TNF- $\alpha$  suppression.

Liver-type arginase is a highly sensitive marker for hepatocellular damage in rats [40]. In the present study, the immunoreactivity of antiliver arginase in the hepatic tissues of the control

group was low. There was an obviously increase in the antiliver arginase immunoreactivity of the I/R group. In the I/R+IFX group, there was low antiliver arginase immunoreactivity. The histopathological results of this study were similar to other studies [40, 41]. Liver function is crucial in maintaining the barrier properties of the hepatocytes against invasion of inflammatory cells, which many believe contribute to reperfusion injury. Preservation of hepatocytes function will reduce the influx of inflammatory cells. Inflammatory cytokines, such as TNF- $\alpha$  and IL-6, have been shown to play key roles in the pathophysiology of hepatic I/R injury. In the previous studies showed that I/R injury of the liver reduced by blocking liver arginase (decrease TNF- $\alpha$  and IL-6). Liver arginase blockade protect hepatic I/R injury by minimizing organ damage associated with inflammation and cellular necrosis [42, 43]. In our study the antiliver arginase immunoreactivity of IFX applied group was lower than I/R group. These effects were attributed to possible anti-TNF- $\alpha$  effects of IFX.

In conclusion, I/R-caused liver injury can be prevented with prior IFX treatment. This liver protective effect of IFX may be related to antioxidant and anti-TNF- $\alpha$  efficacies. We propose that, for the relief of liver injury subsequent to transplantation, liver resection, trauma, and shock, tentative treatments can be incorporated with IFX, which is already approved for clinical use.

### Disclosure of conflict of interest

None.

**Address correspondence to:** Ahmet Fikret Yucel, Department of Surgery, School of Medicine, Recep Tayyip Erdogan University, Rize 53100, Turkey. Tel: +904642123009; Fax: +904642123015; E-mail: ahmetfy@yahoo.com

### References

- [1] Glantzounis GK, Salacinski HJ, Yang W, Davidson BR, Seifalian AM. The contemporary role of antioxidant therapy in attenuating liver ischemia-reperfusion injury: a review. *Liver Transpl* 2005; 11: 1031-47.
- [2] Delva E, Camus Y, Nordlinger B, Hannoun L, Parc R, Deriaz H, Lienhart A, Huguet C. Vascular occlusions for liver resections. Operative management and tolerance to hepatic ischemia: 142 cases. *Ann Surg* 1989; 209: 211-8.



## Infliximab on acute hepatic injury

- [3] McCord JM. Oxygen derived free radicals in postischemic tissues. *N Engl J Med* 1985; 312: 159-163.
- [4] Jaeschke H. Mechanisms of reperfusion injury after warm ischemia to the liver. *J Hepatobiliary Pancreat Surg* 1998; 5: 402-408.
- [5] Teoh NC, Farrell GC. Hepatic ischemia reperfusion injury: pathogenic mechanisms and basis for hepatoprotection. *J Gastroenterol Hepatol* 2003; 18: 891-902.
- [6] Jaeschke H. Molecular mechanisms of hepatic ischemia-reperfusion injury and preconditioning. *Am J Physiol Gastrointest Liver Physiol* 2003; 284: 15-26.
- [7] Streieter RM, Kunkel SL, Bone RC. Role of tumour necrosis factor in disease states and inflammation. *Crit Care Med* 1993; 21: 447-63.
- [8] Thornton AJ, Strieter RM, Lindley I, Baggiolini M, Kunkel SL. Cytokine-induced gene expression of a neutrophil chemotactic factor/IL-8 in human hepatocytes. *J Immunol* 1990; 144: 2609-13.
- [9] Colletti LM, Kunkel SL, Walz A, Burdick MD, Kunkel RG, Wilke CA, Strieter RM. The role of cytokine networks in the local liver injury following hepatic ischemia/reperfusion in the rat. *Hepatology* 1996; 23: 506-14.
- [10] Shibuya H, Ohkohchi N, Tsukamoto S, Satomi S. Tumour necrosis factor-induced, superoxide-mediated neutrophil accumulation in cold ischemia/reperfusion in rat liver. *Hepatology* 1997; 26: 113-20.
- [11] Shirasugi N, Wakabayashi G, Shimazu M, Oshima A, Shito M, Kawachi S, Karahashi T, Kumamoto Y, Yoshida M, Kitajima M. Up-regulation of oxygen-derived free radicals by interleukin-1 in hepatic ischemia/reperfusion injury. *Transplantation* 1997; 64: 1398-403.
- [12] Shito M, Wakabayashi G, Ueda M, Shimazu M, Shirasugi N, Endo M, Mukai M, Kitajima M. Interleukin 1 receptor blockade reduces tumour necrosis factor production, tissue injury, and mortality after hepatic ischemia-reperfusion in the rat. *Transplantation* 1997; 63: 143-8.
- [13] Suzuki S, Toledo-Pereyra LH. Interleukin 1 and tumor necrosis factor production as the initial stimulants of liver ischemia and reperfusion injury. *J Surg Res* 1994; 57: 253-8.
- [14] Sartani G, Silver PB, Rizzo LV, Chan CC, Wiggert B, Mastorakos G, Caspi RR. Anti-tumor necrosis factor alpha therapy suppresses the induction of experimental autoimmune uveoretinitis in mice by inhibiting antigen priming. *Invest Ophthalmol Vis Sci* 1996; 37: 2211-8.
- [15] Di Sabatino A, Ciccocioppo R, Benazzato L, Sturniolo GC, Corazza GR. Infliximab downregulates basic fibroblast growth factor and vascular endothelial growth factor in Crohn's disease patients. *Aliment Pharmacol Ther* 2004; 19: 1019-24.
- [16] Cury DH, Costa JE, Irika K, Mijji L, Garcez A, Buchiguel C, Silva I, Sipahi A. Protective effect of octreotide and infliximab in an experimental model of indomethacin-induced inflammatory bowel disease. *Dig Dis Sci* 2008; 53: 2516-20.
- [17] Pascher A, Klupp J, Langrehr JM, Neuhaus P. Anti-TNF-alpha therapy for acute rejection in intestinal transplantation. *Transplant Proc* 2005; 37: 1635-6.
- [18] Pergel A, Zengin K, Cercel A, Aki H, Kaya S. The effects of somatostatin and ursodeoxycholic acid in preventing the ischemic injury of the liver following Pringle maneuver in obstructive jaundice-rat model. *Hepatogastroenterology* 2007; 54: 229-33.
- [19] Draper HH, Squires EJ, Mahmoodi H, Wu J, Agarwal S, Hadley M. A comparative evaluation of thiobarbituric acid methods for the determination of malondialdehyde in biological materials. *Free Radic Biol Med* 1993; 15: 353-63.
- [20] Paglia DE, Valentine WN. Studies on the quantitative and qualitative characterization of erythrocyte glutathione peroxidase. *J Lab Clin Med* 1967; 70: 158-169.
- [21] Chiu CJ, McArdle AH, Brown R, Scott HJ, Gurd FN. Intestinal mucosal lesion in low-flow states. I. A morphological, hemodynamic, and metabolic reappraisal. *Arch Surg* 1970; 101: 478-83.
- [22] Klune JR, Tsung A. Molecular biology of liver ischemia/reperfusion injury: established mechanisms and recent advancements. *Surg Clin North Am* 2010; 90: 665-677.
- [23] Czubkowski P, Socha P, Pawlowska J. Current status of oxidative stress in pediatric liver transplantation. *Pediatr Transplant* 2010; 14: 169-77.
- [24] Niemelä O, Alatalo P. Biomarkers of alcohol consumption and related liver disease. *Scand J Clin Lab Invest* 2010; 70: 305-12.
- [25] Dulundu E, Ozel Y, Topaloglu U, Sehirlir O, Ercan F, Gedik N, Sener G. Alpha-lipoic acid protects against hepatic ischemia-reperfusion injury in rats. *Pharmacology* 2007; 79: 163-70.
- [26] Park SW, Lee SM. Antioxidant and prooxidant properties of ascorbic acid on hepatic dysfunction induced by cold ischemia/reperfusion. *Eur J Pharmacol* 2008; 580: 401-406.
- [27] Dalle-Donne I, Rossi R, Colombo R, Giustarini D, Milzani A. Biomarkers of oxidative damage in human disease. *Clin Chem* 2006; 52: 601-23.
- [28] Yucel AF, Kanter M, Pergel A, Erboga M, Guzel A. The role of curcumin on intestinal oxidative stress, cell proliferation and apoptosis after ischemia/reperfusion injury in rats. *J Mol Histol* 2011; 42: 579-87.

## Infliximab on acute hepatic injury

- [29] Pergel A, Kanter M, Yucel AF, Aydin I, Erboga M, Guzel A. Anti-inflammatory and antioxidant effects of infliximab in a rat model of intestinal ischemia/reperfusion injury. *Toxicol Ind Health* 2012; 28: 923-32.
- [30] Husted TL, Lentsch AB. The role of cytokines in pharmacological modulation of hepatic ischemia/reperfusion injury. *Curr Pharm Design* 2006; 12: 2867-73.
- [31] Clavien PA, Yadav S, Sindram D, Bentley RC. Protective effects of ischemic preconditioning for liver resection performed under inflow occlusion in humans. *Ann Surg* 2000; 232: 155-62.
- [32] Guzel A, Kanter M, Guzel A, Yucel AF, Erboga M. Protective effect of curcumin on acute lung injury induced by intestinal ischaemia/reperfusion. *Toxicol Ind Health* 2013; 29: 633-42.
- [33] Garcia-Criado FJ, Toledo-Pereyra LH, Lopez-Neblina F, Phillips ML, Paez-Rollys A, Misawa K. Role of P-selectin in total hepatic ischemia and reperfusion. *J Am Coll Surg* 1995; 181: 327-34.
- [34] Lentsch AB, Yoshidome H, Cheadle WG, Miller FN, Edwards MJ. Chemokine involvement in hepatic ischemia/reperfusion injury in mice: roles for macrophage inflammatory protein-2 and KC. *Hepatology* 1998; 27: 1172-7.
- [35] Vollmar B, Glasz J, Menger MD, Messmer K. Leukocytes contribute to hepatic ischemia/reperfusion injury via intercellular adhesion molecule-1-mediated venular adherence. *Surgery* 1995; 117: 195-200.
- [36] Marubayashi S, Oshiro Y, Maeda T, Fukuma K, Okada K, Hinoi T, Ikeda M, Yamada K, Itoh H, Dohi K. Protective effect of monoclonal antibodies to adhesion molecules on rat liver ischemia-reperfusion injury. *Surgery* 1997; 122: 45-52.
- [37] Yamashita M, Katsumata M, Iwashima M, Kimura M, Shimizu C, Kamata T, Shin T, Seki N, Suzuki S, Taniguchi M, Nakayama T. T cell receptor-induced calcineurin activation regulates T helper type 2 cell development by modifying the interleukin 4 receptor signaling complex. *J Exp Med* 2000; 191: 1869-79.
- [38] Rusnak F, Mertz P. Calcineurin: form and function. *Physiol Rev* 2000; 80: 1483-521.
- [39] Kalkan Y, Tmkaya L, Bostan H, Tomak Y, Yılmaz A. Effects of sugammadex on immunoreactivity of calcineurin in rat testes cells after neuromuscular block: a pilot study. *J Mol Histol* 2012; 43: 235-41.
- [40] Ikemoto M, Tsunekawa S, Toda Y, Totani M. Liver-type arginase is a highly sensitive marker for hepatocellular damage in rats. *Clin Chem* 2001; 47: 946-8.
- [41] Cure E, Cure MC, Tmkaya L, Kalkan Y, Aydin I, Kirbas A, Yılmaz A, Yuce S, Gokce MF. Topiramate ameliorates abdominal aorta cross-clamping induced liver injury in rats. *Saudi J Gastroenterol* 2014; 20: 297-303.
- [42] Reid KM, Tsung A, Kaizu T, Jeyabalan G, Ikeda A, Shao L, Wu G, Murase N, Geller DA. Liver I/R injury is improved by the arginase inhibitor, N(omega)-hydroxy-nor-L-arginine (nor-NOHA). *Am J Physiol Gastrointest Liver Physiol* 2007; 292: 512-7.
- [43] Jeyabalan G, Klune JR, Nakao A, Martik N, Wu G, Tsung A, Geller DA. Arginase blockade protects against hepatic damage in warm ischemia-reperfusion. *Nitric Oxide* 2008; 19: 29-35.