

## RESEARCH

# The estimation of the volume of sheep mandibular defects using cone-beam computed tomography images and a stereological method

S Kayipmaz<sup>\*1</sup>, ÖS Sezgin<sup>1</sup>, ST Sarıcaoğlu<sup>1</sup>, O Baş<sup>2</sup>, B Şahin<sup>3</sup> and M Küçük<sup>4</sup>

<sup>1</sup>Karadeniz Technical University Faculty of Dentistry, Department of Oral Diagnosis and Radiology, Trabzon, Turkey; <sup>2</sup>Rize University Faculty of Medicine Department of Anatomy, Rize, Turkey; <sup>3</sup>Ondokuz Mayıs University Faculty of Medicine, Department of Anatomy, Samsun, Turkey; <sup>4</sup>Karadeniz Technical University Faculty of Arts and Sciences, Department of Chemistry, Trabzon, Turkey

**Objective:** The Cavalieri principle of stereological methods is widely used to estimate the volume of structures. Recently in clinical practice, it has become common to use this approach for daily routine purposes. The Cavalieri principle provides quantitative and unbiased volume estimates which are independent of the observer. In the present study, the efficacy of using the Cavalieri principle to estimate the volume of sheep mandibular defects on cone beam CT (CBCT) scans was tested.

**Methods:** 24 differently sized defects were created on 4 sheep mandibles. Before the defects were created, the outer boundaries of the defects were determined using plaster casts. CBCT scans of the defects were taken. The scans were reconstructed in the coronal plane and sections of 0.2 mm thickness with 0.2 mm and 0.4 mm intervals were obtained. The volume of each defect was estimated using the Cavalieri principle. The models were created using light-body silicone for the estimation of the actual volume of each defect. They were immersed in water using a pycnometer and the actual volumes were obtained on the basis of the Archimedean principle. The actual and estimated volumes of the defects were compared using the Wilcoxon signed-rank test.

**Results:** The results showed that the volumes from the Cavalieri estimates did not differ from the actual volumes of the defects ( $P > 0.05$ ).

**Conclusion:** We concluded that the volume of mandibular defects can be accurately estimated using the Cavalieri principle on images from a CBCT scan.

*Dentomaxillofacial Radiology* (2011) **40**, 165–169. doi: 10.1259/dmfr/23067462

**Keywords:** cone beam computed tomography; quantitative evaluation

## Introduction

Intraoral and extraoral radiography are widely used in the diagnosis and follow up of dental and maxillofacial lesions. In recent years, cone beam CT (CBCT)—a three-dimensional (3D) imaging method—has provided many innovations in dentistry. A CBCT system ensures better analysis of the morphologies of lesions and defects in the jaw, as well as the determination of dental caries, roots and jaw fractures.<sup>1–4</sup> The dose of radiation in CBCT is less than that in medical CT devices.<sup>5</sup> Additionally, volumetric analyses may be performed

using CBCT devices and the prognosis of lesions may be quantitatively observed.<sup>6</sup> Quantitative measurements may be performed using certain software in CBCT systems.<sup>7,8</sup>

The Cavalieri principle, a stereological method, is an effective method in volumetric measurements of biological structures. The Cavalieri principle provides numerical values expressing precise and unbiased quantitative measurements.<sup>9,10</sup> It was first defined by the Italian mathematician Bonaventura Cavalieri approximately 350 years ago. In this principle, sections of an object that are parallel and of equal thickness are taken, and the volume of the object is calculated by the total number of section areas and thickness of the section. CT, MRI or ultrasonography section imaging

\*Correspondence to: Saadetin Kayipmaz, Karadeniz Technical University Faculty of Dentistry, Department of Oral Diagnosis and Radiology, 61080 Trabzon/Turkiye; E-mail: [kayipmaz@ktu.edu.tr](mailto:kayipmaz@ktu.edu.tr); [skayitmaz@yahoo.com](mailto:skayitmaz@yahoo.com)  
Received 2 April 2010; revised 7 June 2010; accepted 13 June 2010

may be used in the calculation of the volume of an object using the Cavalieri principle.<sup>11–14</sup>

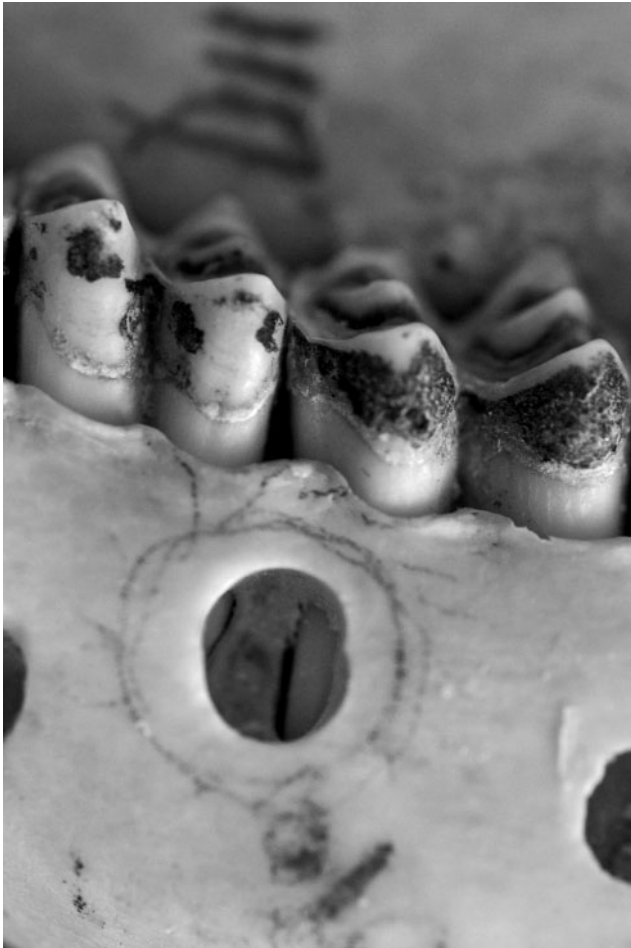There have been a limited number of quantitative studies carried out on the use of CBCT systems and software in volumetric analysis in dentistry.<sup>6–8</sup>

The aim of this study is to test the efficacy of using the Cavalieri principle to estimate the volume of sheep mandibular defects based on CBCT scans.

## Materials and methods

Four dry sheep mandibles were selected for the study. 24 differently sized defects were created on the vestibular side of the mandibles using a tungsten carbide burr (Figure 1). The size of the defects varied between 2 mm and 12 mm in diameter. Before the creation of the defects, the outer boundaries of the defects were determined using plaster casts.

CBCT scans of the defects were taken with a new CBCT system (Kodak 9500 Cone Beam 3D System, Kodak Dental Systems, Carestream Health, Rochester, NY) (Figure 2). This system has 2 field of views (FOVs) (9 × 15 cm and 18.4 × 20.6 cm), a minimum 0.2 mm



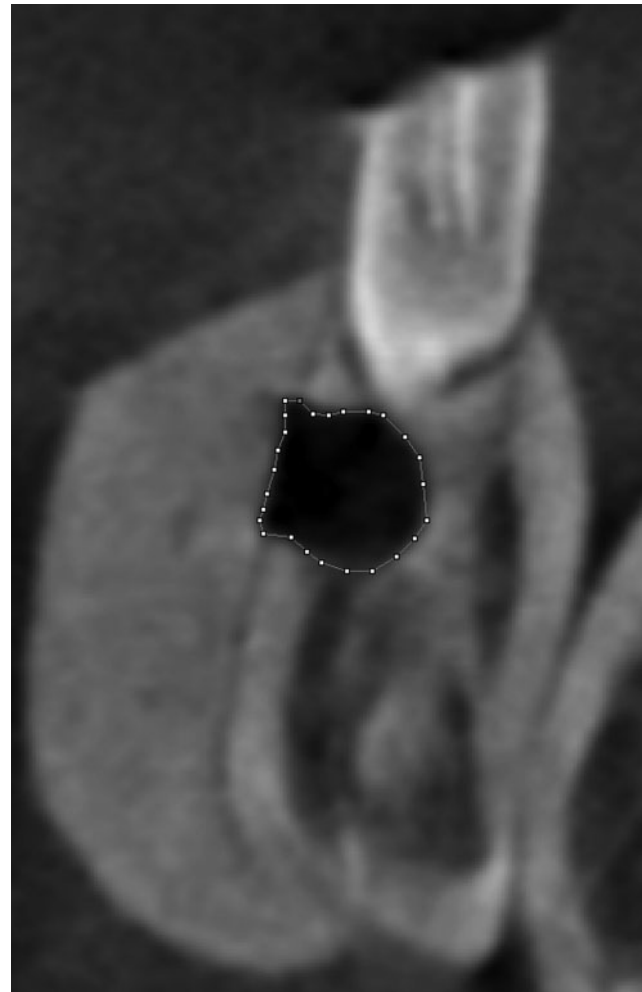
**Figure 1** Bone defect created with a burr on the vestibular side of the sheep mandible

voxel size and a 10.8 s scan time. The small FOV was used for the volumetric analysis of the defects. Tap water was used to simulate soft tissue. Volumetric data were reconstructed and sectioned into 0.2 mm in the coronal plane, and sections of 0.2 mm thickness with 0.2 mm and 0.4 mm intervals were obtained. The volume of each defect was estimated using the Cavalieri principle and the planimetry technique. The surface area of each section was measured by means of the planimetry method, using ImageJ software (ImageJ, 1.37v: <http://rsb.info.nih.gov/ij/>) (Figure 2). Each measurement was performed three times by one observer using the tools of the software. The average score was used for calculation. The sum of the areas was used to estimate the volume using the following formula, which has been described in previous reports:<sup>12–14</sup>

$$V = t \times \Sigma A,$$

where  $t$  is the section thickness of consecutive sections and  $\Sigma A$  is the total sectional area of the consecutive sections.

After the calculations, bone defect models were created using light-body silicone for the estimation of the actual



**Figure 2** A cone beam CT scan of a defect in the frontal plane. The scan thickness was 0.2 mm and estimation of defect volume was made by using planimetry method

volume of each defect. The models were immersed into a pycnometer filled with water, and the actual volumes were calculated from the density and weight of the water run over based on Archimedean principle.

The data were analysed using the Statistical Package for the Social Sciences for Windows, version 12 (SPSS, Chicago, IL). The liquid pycnometer method based on Archimedean principle served as the gold standard for the testing method. The volumetric evaluation of the CBCT systems was assessed using a normality test (Kolmogorov–Smirnov). There was no distribution of normality test, therefore the Wilcoxon signed-rank test was performed to compare the results of Cavalieri principle and the pycnometric method. The level of statistical significance was set at 0.05.

### Results

The mean and standard deviation (SD) of the defect volume measured by the pycnometric method was 0.103 ml (SD 0.072 ml). The result of the Cavalieri principle was 0.105 ml (SD 0.074 ml). The details of the results are presented in Table 1. The tests demonstrated that the volumes from the Cavalieri estimates did not differ from the actual volumes of the defects ( $P > 0.05$ ) (Table 1). A 95% confidence interval is presented in Table 2. A scatter graph shows the relationship between the Archimedean and Cavalieri principles (Figure 3). The results of the defect volumes estimates using the two principles are shown in Table 3. The differences between the volumes of the Cavalieri principle and the Archimedean principle were between 0 ml and 0.0276 ml. The mean difference in the volumes from the two principles was 0.00873 ml (SD 0.00792 ml). The range between the two principles was 0.0276 ml.

### Discussion

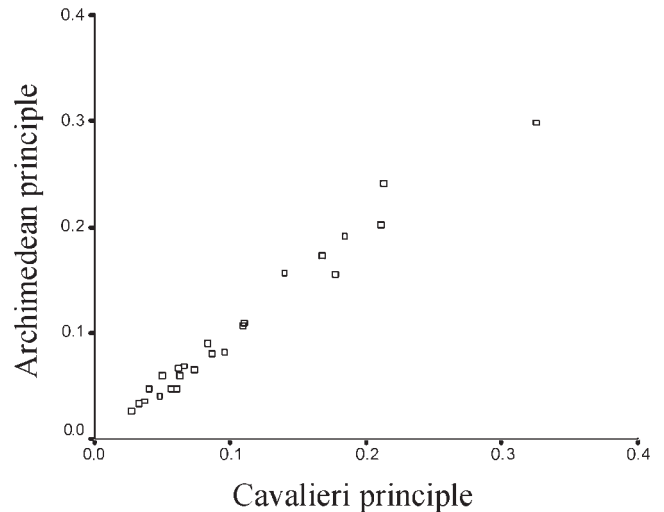
Bone defects may be caused by various factors, such as periapical infection, cysts, tumours and periodontal disease. Extraoral and intraoral radiographic techniques are used in the treatment and prognosis of these lesions. Assessments performed in this respect are generally two

**Table 1** Statistical significance of the Cavalieri principle and Archimedean principle

	<i>Cavalieri principle—Archimedean principle</i>
Z	-0.714
Asymptotic significance (2-tailed)	0.475

**Table 2** Comparisons of the results of the Cavalieri principle and Archimedean principle

	<i>95% confidence interval of the difference</i>	
	<i>Archimedean principle</i>	<i>Cavalieri principle</i>
Lower bound	0.0729	0.0740
Upper bound	0.1340	0.1360



**Figure 3** Scatter graph of bone defects as measured by the pycnometric method based on Archimedean principle vs the planimetric method based on Cavalieri principle

dimensional (2D). It is possible to make 3D analyses of oral structures using dental CBCT devices.<sup>6</sup> We assessed defect volumes in CBCT images in our study using the Cavalieri principle and with the planimetry technique, the efficiency of which has been proven in many studies.<sup>9–14</sup>

Extraoral and intraoral radiographs are frequently used before and after the treatment of lesions. The healing of periapical lesions may be efficiently observed, especially by intraoral radiography. In these applications, the contraction of a lesion area of a radiogram is considered as a healing criterion.<sup>15–17</sup> This method is a 2D application that may be used in many types of lesions.

Dental CBCT devices may provide sectional images like medical CT devices. It is possible to make 3D assessments and quantitative measurements using these

**Table 3** The volumes measured by the two principles (ml)

<i>No.</i>	<i>Archimedean</i>	<i>Cavalieri</i>	<i>Difference</i>
1	0.0265	0.0282	0.0017
2	0.1079	0.1095	0.0016
3	0.0471	0.0401	0.0070
4	0.155	0.1773	0.0223
5	0.0666	0.0621	0.0045
6	0.2412	0.2136	0.0276
7	0.1913	0.185	0.0063
8	0.1732	0.168	0.0052
9	0.2984	0.326	0.0276
10	0.1566	0.1400	0.0166
11	0.0600	0.0500	0.0100
12	0.0814	0.087	0.0056
13	0.2023	0.2109	0.0086
14	0.1104	0.1104	0.0000
15	0.0826	0.096	0.0134
16	0.0651	0.074	0.0089
17	0.0482	0.0571	0.0089
18	0.0333	0.0333	0.0000
19	0.0692	0.0661	0.0031
20	0.0895	0.0834	0.0061
21	0.0597	0.0632	0.0035
22	0.0474	0.061	0.0136
23	0.0413	0.048	0.0067
24	0.0359	0.0366	0.0007

sections. A study involving the follow-up treatment of extraction sockets in patients receiving radiotherapy showed that dental CBCT devices may be used quantitatively.<sup>6</sup> Furthermore, dental CBCT devices have been used in the volumetric analysis of extraction sockets.<sup>7</sup> In another study, a dental CBCT device was used to measure airway volume in obstructive sleep apnoea syndrome.<sup>8</sup> In these studies, volumetric analyses were performed using special software.

In our study, we used the Cavalieri principle, a stereological method, in the quantitative assessment of defect volumes without using any special software. The assessment of biological structures using the Cavalieri principle may be performed with either the planimetric or the point-counting method.<sup>18</sup> We only used the planimetric method in this study.

In this study, there is no statistically significant difference between the stereological measurement made by the CBCT device and the actual volume ( $P > 0.05$ ) of the defect measured by the pycnometric method based on Archimedean principle. This finding showed that the use of the Cavalieri principle is an effective method for measuring volume in Kodak 9500 CBCT images. Underestimation was observed in 9 samples, the same result was observed in 2 samples and overestimation was observed in the remaining 13 samples.

The image quality of CBCT devices, which depends on section thickness, voxel dimension and focal spot dimension, may affect volume calculations. Agbaje *et al*<sup>7</sup> performed volumetric analyses of extraction sockets on human mandibles and maxillae. They reported that the image quality was better because the compact structure of mandible and mandibular sockets were closer to the actual volumes, although there was no statistical difference. This result may be associated with the effect of image quality.

A reason for the lower calculation of defect volumes is the lower calculation tendency of volumes of radiolucent structures in radiopaque structures. This situation has been found both in a study related to the calculation of intracranial volume and in a study involving volumetric analyses of extraction sockets.<sup>7,18</sup> If the intensities of the target tissue and surrounding structures are not close to each other in the cross-sectional images, and if a voxel comprises different intensities, the calculated volume does not match the actual volume. The reason for that is the difference of X-ray attenuation is larger in imaging the tissues with different intensities.<sup>19</sup> This situation is known as the partial volume effect. In order to reduce this effect, it is necessary to select thin sections. Therefore, such section thicknesses have been identified to

ensure more realistic volumetric analyses in CT studies.<sup>20</sup> The defects we studied in the present study were mostly in oval form and were created in the intensive bone tissue. In other studies involving the analysis of the effect of section thickness on volumetric analyses, it was demonstrated that when section thickness is thin, the problem of underestimation is reduced.<sup>21,22</sup>

The overestimation effect has been explained by Gadeberg *et al*<sup>23</sup> as wider section thickness in MR images. Some of the defects used in our study are such defects in a diameter of almost 2 mm. The section thickness was selected as 0.2 mm. It may be assumed that a section thickness of 0.2 mm and an interval of 0.2 mm and 0.4 mm positively contribute to the volumetric analysis of lesions. The results of the study indicated that there was no statistical difference between the two techniques.

It was shown in some studies using the Cavalieri principle that there is no difference between observers.<sup>21</sup> In this study, the measurements were performed by a single observer.

Two studies involving intracranial volume analysis and volumetric analyses of extraction sockets included analysis of anatomic formations.<sup>7,18</sup> The peripheral structures of the cranium and extraction sockets in both studies were naturally formed bone cortices; for example, the existence of lamina dura in the extraction sockets positively affects the edge of sockets in radiography. Good detail is a characteristic sought in the assessment of each section analysed. The defects in our study were artificially prepared. Lesion boundaries ended within bone trabeculae. Therefore, lesion borders were not clear along with the entire lesion periphery. It was difficult to determine the boundaries of sections owing to this characteristic in some of the specimens.

We used direct frontal planes of defects in CBCT. Other planes and zoom options may also be used with this device. The plane worked by stereological methods has no adverse effect on quantitative measurements.<sup>20,24</sup> Therefore, we used only frontal section images in the study.

In conclusion, the Cavalieri principle used on CBCT images was a valid method for the volumetric analysis of sheep mandible defects. Since the volumetric analysis of the artificial defects that we created in the study could be carried out by this method effectively, we think that this quantitative method can be used in the follow-up of many bone lesions in the future.

This study was presented as a poster presentation at the 12<sup>th</sup> European Congress of Dento-Maxillofacial Radiology on 2-5 June 2010 in Istanbul, Turkey.

## References

1. Akdeniz BG, Gröndahl H, Magnusson B. Accuracy of proximal caries depth measurements: comparison between limited cone beam computed tomography, storage phosphor and film radiography. *Caries Res* 2006; **40**: 202–207.
2. Bornstein MM, Wiest R, Balsiger R, Reichart PA. Anterior Stafne's bone cavity mimicking a periapical lesion of endodontic origin: report of two cases. *J Endod* 2009; **35**: 1598–1602.
3. Vandenberghe B, Jacobs R, Yang J. Diagnostic validity (or acuity) of 2D CCD versus 3D CBCT-images for assessing periodontal breakdown. *Oral Surg Oral Med Oral Pathol Oral Radiol Endod* 2007; **104**: 395–401.
4. Dölekoğlu S, Fişekçioğlu E, İlgüy D, İlgüy M, Bayirli G. Diagnosis of jaw and dentoalveolar fractures in a traumatized patient with cone beam computed tomography. *Dent Traumatol* 2010; **26**: 200–203.



5. Ludlow JB, Ivanovic M. Comparative dosimetry of dental CBCT devices and 64-slice CT for oral and maxillofacial radiology. *Oral Surg Oral Med Oral Pathol Oral Radiol Endod* 2008; **106**: 106–114.
6. Agbaje JO, Jacobs R, Michiels K, Abu-Ta'a M, van Steenberghe D. Bone healing after dental extractions in irradiated patients: a pilot study on a novel technique for volume assessment of healing tooth sockets. *Clin Oral Investig* 2009; **13**: 257–261.
7. Agbaje JO, Jacobs R, Maes F, Michiels K, van Steenberghe D. Volumetric analysis of extraction sockets using cone beam computed tomography: a pilot study on ex vivo jaw bone. *J Clin Periodontol* 2007; **34**: 985–990.
8. Ogawa T, Enciso R, Shintaku WH, Clark GT. Evaluation of cross-section airway configuration of obstructive sleep apnea. *Oral Surg Oral Med Oral Pathol Oral Radiol Endod* 2007; **103**: 102–108.
9. Gundersen HJ, Jensen EB. The efficiency of systematic sampling in stereology and its prediction. *J Microsc* 1987; **147**: 229–263.
10. Mayhew TM, Gundersen HJG. 'If you assume, you can make an ass out of u and me': a decade of the disector for stereological counting of particles in 3D space. *J Anat* 1996; **188**: 1–15.
11. Roberts N, Puddephat MJ, McNulty V. The benefit of stereology for quantitative radiology. *Br J Radiol* 2000; **73**: 679–697.
12. Mazonakis M, Damilakis J, Maris T, Prassopoulos P, Gourtsoyiannis N. Comparison of two volumetric techniques for estimating liver volume using magnetic resonance imaging. *J Magn Reson Imaging* 2002; **15**: 557–563.
13. Sahin B, Alper T, Kokcu A, Malatyalioglu E, Kosif R. Estimation of the amniotic fluid volume using the Cavalieri method on ultrasound images. *Int J Gynaecol Obstet* 2003; **82**: 25–30.
14. Acer N, Sahin B, Bas O, Ertekin T, Usanmaz M. Comparison of three methods for the estimation of total intracranial volume: stereologic, planimetric, and anthropometric approaches. *Ann Plast Surg* 2007; **58**: 48–53.
15. De Rossi A, Silva LA, Leonardo MR, Rocha LB, Rossi MA. Effect of rotary or manual instrumentation, with or without a calcium hydroxide/1% chlorhexidine intracanal dressing, on the healing of experimentally induced chronic periapical lesions. *Oral Surg Oral Med Oral Pathol Oral Radiol Endod* 2005; **99**: 628–636.
16. Delantoni A, Papademitriou P. An unusually large asymptomatic periapical lesion that presented as a random finding on a panoramic radiograph. *Oral Surg Oral Med Oral Pathol Oral Radiol Endod* 2007; **104**: 62–65.
17. Ricucci D, Lin LM, Spångberg LS. Wound healing of apical tissues after root canal therapy: a long-term clinical, radiographic, and histopathologic observation study. *Oral Surg Oral Med Oral Pathol Oral Radiol Endod* 2009; **108**: 609–621.
18. Sahin B, Acer N, Sonmez OF, Emirzeoglu M, Basaloglu H, Uzun A, et al. Comparison of four methods for the estimation of intracranial volume: a gold standard study. *Clin Anat* 2007; **20**: 766–773.
19. Nawaratne S, Fabiny R, Brien J, Zalcborg J, Cosolo W, Whan A, et al. Accuracy of volume measurement using helical CT. *J Comput Assist Tomogr* 1997; **21**: 481–486.
20. Sahin B, Mazonakis M, Akan H, Kaplan S, Bek Y. Dependence of computed tomography volume measurements upon section thickness: an application to human dry skulls. *Clin Anat* 2008; **21**: 479–485.
21. Emirzeoglu M, Sahin B, Selcuk MB, Kaplan S. The effects of section thickness on the estimation of liver volume by the Cavalieri principle using computed tomography images. *Eur J Radiol* 2005; **56**: 391–397.
22. Sahin B, Ergur H. Assessment of the optimum section thickness for the estimation of liver volume using magnetic resonance images: a stereological gold standard study. *Eur J Radiol* 2006; **57**: 96–101.
23. Gadeberg P, Gundersen HJ, Tågehøj F. How accurate are measurements on MRI? a study on multiple sclerosis using reliable 3D stereological methods. *J Magn Reson Imaging* 1999; **10**: 72–79.
24. Sahin B, Emirzeoglu M, Uzun A, Incesu L, Bek Y, Bilgic S, et al. Unbiased estimation of the liver volume by the Cavalieri principle using magnetic resonance images. *Eur J Radiol* 2003; **47**: 164–170.