

See discussions, stats, and author profiles for this publication at: <https://www.researchgate.net/publication/287642395>

Comparative Review of Biochemistry and Cell Anatomy of the Hepatic Tissue in Rats Administered Some Anti Hypertensive Drug for a Long Time

Article in *LATIN AMERICAN JOURNAL OF PHARMACY* · May 2012

CITATIONS

5

READS

340

8 authors, including:



Ismail Malkoç

Duzce University

52 PUBLICATIONS 274 CITATIONS

SEE PROFILE



Nihal Cetin

Selcuk University

59 PUBLICATIONS 643 CITATIONS

SEE PROFILE



Ahmet Hacimuftuoglu

Ataturk University

295 PUBLICATIONS 3,037 CITATIONS

SEE PROFILE



Nesrin Gursan

Ataturk University

68 PUBLICATIONS 941 CITATIONS

SEE PROFILE



Comparative Review of Biochemistry and Cell Anatomy of the Hepatic Tissue in Rats Administered Some Anti Hypertensive Drug for a Long Time

Ismail MALKOC¹, Nihal CETIN², Durdu ALTUNER³, Ahmet HACIMUFTUOGLU²,
Nesrin GURSAN⁴, Ebubekir BAKAN⁵, Fatih AKCAY⁵ & Halis SULEYMAN^{2*}

¹ Faculty of Medicine, Department of Anatomy, ² Department of Pharmacology, ⁴ Department of Pathology,

⁵ Department of Biochemistry, Ataturk University, Erzurum-Turkey

³ Faculty of Medicine, Department of Pharmacology, Rize University, Rize-Turkey

SUMMARY. The adverse biochemical and structural effects of antihypertensive drugs over a long period (clonidine, methyldopa, rilmenidine, amlodipine, ramipril) on hepatic tissue has been examined in this study. The results are considered to be beneficial for the identification of indications and contraindications in hypertensive patients. Severe bile duct proliferation, portal inflammation, interface hepatitis, focal necrosis and hepatocyte degeneration were demonstrated in the clonidine and amlodipine groups, which had higher oxidant parameters, aspartate aminotransferase, alanine amino transferase and lactate dehydrogenase activity and a higher amount of 8-OH Gua. In the group receiving rilmenidine, all the histopathological findings were the same as those in the clonidine and amlodipine groups, except for bile duct proliferation and interface hepatitis. On histopathological examination of the cell anatomy, it was shown that methyldopa and ramipril caused mild liver damage. While clonidine and amlodipine gave rise to severe liver damage, rilmenidine caused moderate damage, and methyldopa and ramipril led to mild loss of liver function.

INTRODUCTION

Hypertension is among the leading chronic health problems in the world¹. Hypertension is an important cause of mortality and morbidity in adults. Therefore, the treatment of hypertension is very important. As a result, various antihypertensive medications are used. Adequate regular therapy is required to prevent hypertension and its complications². The objective of hypertension therapy is to reduce morbidity and mortality related to cardiovascular, cerebrovascular, renal and other organ complications³. Clinical studies have shown that the majority of patients were seen to have received better antihypertensive therapy when two or more drugs had been used^{4,5}. As known, antihypertensive drugs such as centrally acting sympatholytics (clonidine, methyldopa, rilmenidine), angiotensin-converting enzyme inhibitors and calcium channel blockers are commonly used for hypertension therapy⁶. Furthermore, some drugs are consid-

ered to be useful for diseases accompanying hypertension; however, careful elimination of drugs that can be harmful for hypertensive patients with accompanying diseases is essential^{7,8}. Hence, when selecting antihypertensive drugs, one should not only consider the various diseases accompanying hypertension, but the adverse effects of drugs used in hypertension therapy should also be considered.

Methyldopa, clonidine and rilmenidine, which we have assessed in this study, are centrally acting antihypertensive drugs. Rilmenidine is different from methyldopa and clonidine as it shows selectivity for imidazoline-2 receptors (I₂) rather than alpha-2 adrenergic receptors. In this research, we studied two other antihypertensive drugs: amlodipine, an L-type calcium channel blocker, and ramipril, an angiotensin-converting enzyme inhibitor⁶. Arrangement of the antihypertensive drugs for patients who have hepatic

KEY WORDS: Amlodipine, Clonidine, Methyldopa, Rat, Rilmenidine.

* Author to whom correspondence should be addressed. E-mail: halis.suleyman@gmail.com

problems is becoming a major difficulty. In the literature search, we encountered no information related to the comparative study of biochemical and structural toxic effects in hepatic tissue due to long-term administration of these drugs (methyldopa, clonidine, rilmenidine, amlodipine, ramipril) in animals.

The toxic effects of drugs on tissues may be due to biochemical and structural (morphological) factors ⁶. While the structural toxic effects of drugs are shown through histopathological examination, the biochemical toxic effects are evaluated through elevation of oxidant parameters in tissues and the decrease in antioxidant parameters ⁹. Accurate medical treatment of hypertensive patients can only be managed by proper recognition of the biochemical and structural effects of antihypertensive drugs on hepatic tissue. Therefore, the results of this study have many beneficial suggestions for identification of indications and contraindications of these drugs in hypertensive patients.

Hence, the purpose of our study was to measure the oxidant/antioxidant parameters and to histopathologically examine the structural changes in rat hepatic tissue when antihypertensive drugs (clonidine, methyldopa, rilmenidine, amlodipine, ramipril) are administered over a long period.

MATERIAL AND METHODS

Animals

The animals used in the experiment were obtained from the Ataturk University Medical Experimental Application and Research Center. Overall, 60 male Albino Wistar rats weighing 200-210 grams were used for the experiment. Prior to the experiment the animals were housed and fed at normal room temperature (22 °C) in the laboratory in groups.

Chemical Agents

All biochemical assay compounds were purchased from the following sources: Zdorove Drug, Ukraine (clonidine); Eczacıbaşı Drug, Turkey (methyldopa); Pfizer Drug, Turkey (amlodipine); Aventis Drug, Turkey (ramipril); Servier Pharmaceuticals, France (rilmenidine); and IE Ulagay, Turkey (thiopental sodium).

Experimental Procedure

In the experiment, 0.075 mg/kg clonidine, 100 mg/kg methyldopa, 0.5 mg/kg rilmenidine, 2 mg/kg amlodipine and 2 mg/kg ramipril were administered orally to rats daily for three months. As solvent, distilled water in the same

volume was given to healthy rats in the control group. At the end of this period, the animals were sacrificed by administration of a high dose of anaesthetic (thiopental sodium of 50 mg/kg). The biochemical and histopathological examinations were then conducted by resecting the livers of the euthanized animals. The biochemical and histopathological results obtained from the drug groups were evaluated in comparison with the control group.

Biochemical analyses

Total glutathione (tGSH) determination

The amount of GSH in tissue was measured according to the method of Sedlak & Lindsay ¹⁰. The tissue surface of the liver was collected, weighed and then homogenized in 2 mL 50 mM Tris-HCl buffer containing 20 mM EDTA and 0.2 mM sucrose, pH 7.5. The homogenate was immediately precipitated with 0.1 mL of 25 % trichloroacetic acid, and the precipitate was removed by centrifugation at 4,200 rpm for 40 min at 4 °C. The supernatant was used to determine GSH using 5,5'-dithiobis 2-nitrobenzoic acid. Absorbance was measured at 412 nm using a spectrophotometer.

Determination of Myeloperoxidase (MPO) activity

MPO activity was measured according to the modified method of Bradley *et al.* ¹¹. The homogenized samples were frozen and centrifuged at 1,500 g for 10 min at 4 °C. MPO activity in the supernatant was determined by adding 100 µL of the supernatant to 1.9 mL of 10 mmol/L phosphate buffer (pH 6.0) and 1 mL of 1.5 mmol/L *o*-dianisidine hydrochloride containing 0.0005 % (wt/vol) hydrogen peroxide. The changes in absorbance at 450 nm of each sample were recorded on a UV-vis spectrophotometer.

Determination of lipid peroxidation or Malondialdehyde (MDA) formation

The concentrations of tissue lipid peroxidation were determined by estimating MDA using the thiobarbituric acid test ¹². In brief, the rat livers were promptly excised and rinsed with cold saline. To minimize the possibility of interference of haemoglobin with free radicals, blood adhering to the tissue was carefully removed. The tissue was weighed, and homogenized in 10 mL of 100 g/L KCl. The homogenate (0.5 mL) was added to a solution containing 0.2 mL of 80 g/L sodium lauryl sulphate, 1.5 mL of 200 g/L acetic acid, 1.5 mL of 8 g/L 2-thiobarbiturate and 0.3 mL distilled water. The mixture was incubated at 98 °C for 1 h. Upon cooling, 5 mL of *n*-bu-

tanol:pyridine (15: 1) was added. The mixture was vortexed for 1 min and centrifuged for 30 min at 4,000 rpm. The absorbance of the supernatant was measured at 532 nm.

Isolation of DNA from liver tissue

Liver tissue was drawn and DNA was isolated using Shigenaga *et al.*'s modified method¹³. The samples (for liver tissue 50 mg) were homogenized at 4 °C in 1 mL of homogenization buffer (0.1 M NaCl, 30 mM Tris, pH 8.0, 10 mM EDTA, 10 mM 2-mercaptoethanol, 0.5 % [v/v] Triton X-100) with six passes of a Teflon-glass homogenizer at 200 rpm. The samples were centrifuged at 4 °C for 10 min at 1,000 g to pellet nuclei. The supernatant was discarded, and the crude nuclear pellet was re-suspended and re-homogenized in 1 mL extraction buffer (0.1 M Tris, pH 8.0, 0.1 M NaCl, 20 mM EDTA) and re-centrifuged as above for 2 min. The washed pellet was re-suspended in 300 µL of extraction buffer using a wide-orifice 200 µL Pipetman tip. The re-suspended pellet was subsequently incubated at 65 °C for 1 h with the presence of 0.1 mL of 10 % Sodium dodecyl sulfate (SDS), 40 µL proteinase K and 1.9-mL leukocyte lysis buffer. Ammonium acetate was then added to the crude DNA sample to yield a final concentration of 2.5 mol/L and centrifuged in a microcentrifuge for 5 min. The supernatant was removed and mixed with two volumes of ethanol to precipitate the DNA fraction. After centrifugation, the pellet was dried under reduced pressure and dissolved in sterile water. The absorbance of this fraction was measured at 260 and 280 nm. Purification of DNA was determined at a 260/280 ratio 1.8.

DNA hydrolysis with formic acid

Approximately 50 mg of DNA was hydrolysed with 0.5 mL of formic acid (60%, v/v) for 45 min at 150 °C¹⁴. The tubes were allowed to cool. The contents were then transferred to Pierce micro-vials, covered with Kleenex tissues cut to size (secured in place using a rubber band), and cooled in liquid nitrogen. Formic acid was then removed by freeze-drying. Before the analysis, the samples were re-dissolved in the eluent using high performance liquid chromatography (HPLC) (final volume 200 µL).

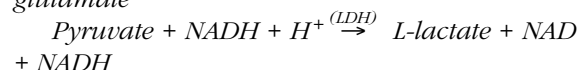
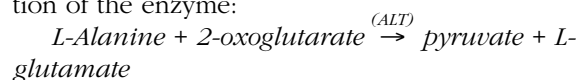
Measurement of 8-hydroxy-2 deoxyguanine (8-OH Gua) with HPLC

The amount of 8-OH Gua and guanine (Gua) was measured using an HPLC system equipped with an electrochemical detector (HP Agilent 1100 module series, E.C.D. HP 1049 A), as previously described^{14,15}. The amounts of 8-

OH Gua and Gua were analyzed on a 250 x 4.6 mm Supelco LC-18-S reverse-phase column. The mobile phase was 50 mM potassium phosphate, pH 5.5, with acetonitrile (97 volume acetonitrile and 3 volume potassium phosphate), and the flow rate was 1.0 mL/min. The detector potential was set at 0.80 V to measure the oxidized base. Gua and 8-OH Gua (25 pmol) were used as standards. The 8-OH Gua levels were expressed as the number of 8-OH Gua molecules/10⁵ Gua molecules¹⁶.

Alanine amino transferase (ALT)

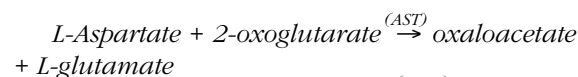
Venous blood samples were collected into tubes without anticoagulant. The serum was separated by centrifugation after clotting and stored at -80 °C until the time of assay. ALT, Aspartate Aminotransferase (AST) and Lactate Dehydrogenase (LDH) (P→L) activity levels were determined in the Cobas 8000 (Roche) photometrical system using the colorimetric method. According to the International Federation of Clinical Chemistry (IFCC), the pyridoxal-5'-phosphate method catalyzes the reaction between 3,4 ALT L-alanine and 2-oxoglutarate. The LDH of pyruvate L-lactate and NAD⁺ generated by the catalyzed reaction undergo reduction to NADH. Pyridoxal phosphate acts as a coenzyme in the amino transfer reaction, ensuring activation of the enzyme:



ALT catalytic activity is directly proportional to the rate of oxidation of NADH.

Aspartate Aminotransferase (AST)

In the sample of 3,4 AST Oxaloacetate and L-glutamate, for the formation of L-aspartate, an amino group with 2-oxoglutarate catalyzes the transfer. Oxaloacetate malate dehydrogenase (MDH) will react in the presence of NADH to generate NAD⁺. Pyridoxal phosphate acts as a coenzyme in the amino transfer reaction.



The NADH oxidation rate is proportional to the catalytic activity of AST.

Lactate dehydrogenase (LDH)

LDH is optimized according to the standard method of the Deutsche Gesellschaft für Klinische Chemie (DGKC). LDH catalyzes the reaction changing pyruvate to L-lactate and NADH to form NAD⁺.

$Pyruvate + NADH + H^+ \rightarrow (LDH) L\text{-lactate} + NAD^+$.

The initial rate of catalytic oxidation of NADH is directly proportional to the LDH activity. This was determined by measuring the decrease in absorbance at 340 nm.

Pathological examination

The specimens were fixed in 10 % formalin and routinely processed for paraffin embedding. For the evaluation, 4 µm thick sections were obtained from each sample and stained with haematoxylin-eosin. On microscopic examination, focal necrosis, interface hepatitis, portal inflammation, bile duct proliferation, vascular anomalies and hepatocyte degeneration were evaluated in 10 separate microscopic fields from two sections. These were scored from 0 to 3.

Statistical analysis

All data were analyzed using the one-way analysis of variance (ANOVA) using SPSS 18.0

software. The differences among the groups were determined using the LSD option, and the level of significance was set at $p < 0,05$. The results were expressed as mean ± standard error of the mean.

RESULTS

MDA, MPO and GSH measurement

As shown in Table 1, while the MDA quantities in the animal hepatic tissues receiving ramipril and methyldopa were almost the same as that of the healthy control group, a significant increase was detected in the rilmenidine group. The MDA level in the clonidine and amlodipine group was seen to have increased at a much greater rate than the others. The increase in MPO activity with respect to healthy control group was observed in the order of ramipril, methyldopa, rilmenidine, clonidine and amlodipine. The amount of GSH was found to be lower in the groups in which MDA and MPO levels were higher.

GROUPS	MDA µmol/gr protein	MPO U/gr	GSH nmol/gr protein	8-OHdG/d
Methyldopa p	4.9 ± 0.48 p < 0.05	2.9 ± 0.8 p > 0.05	3.9 ± 0.12 p < 0.05	1.3 ± 0.28 p < 0.05
Clonidine p	7.7 ± 0.58 P < 0.0001	4.6 ± 0.6 p < 0.0001	2.8 ± 0.7 p < 0.0001	1.9 ± 0.40 p < 0.0001
Rilmenidine p	6.7 ± 0.43 p < 0.001	3.9 ± 0.1 p < 0.001	3.3 ± 0.36 p < 0.0001	1.6 ± 0.28 p < 0.001
AmLodipine p	7.5 ± 0.5 p < 0.0001	5.0 ± 0.8 p < 0.0001	2.3 ± 0.43 p < 0.0001	2.3 ± 0.50 p < 0.0001
Ramipril p	4.2 ± 0.6 p > 0.05	2.5 ± 0.8 p > 0.05	4.8 ± 0.6 p > 0.05	0.9 ± 0.30 p > 0.05
Healthy p	4.0 ± 0.48 -	2.2 ± 0.3 -	5.1 ± 0.7 -	0.7 ± 0.30 -

Table 1. MDA and GSH level, MPO activity and 8-OHdG/d ratio in methyldopa, clonidine, rilmenidine, amlodipine, ramipril and healthy control rat groups. Results are the means ± Standard error of the mean.

	Methyldopa	Clonidine	Rilmenidine	Amlodipine	Ramipril	Control
Proliferation of bile duct	+	+++	++	+++	++	0
Portal inflammation	+	+++	+++	+++	+	0
Interface hepatitis	+	+++	++	+++	+	0
Focal necrosis	++	+++	+++	+++	0	0
Hepatocyte degeneration	+	+++	+++	+++	++	0
Vascular anomalies	0	++	++	++	0	0
Intensity of the total damage	6	17	14	17	6	0

Table 2. Microscopical examine results of the rat hepatic tissue given methyldopa, clonidine, rilmenidine, amlodipine, ramipril and healthy control rat groups. 0: normal tissue, +: mild damage, ++: moderate damage, +++: severe damage.

DNA (8-OH Gua/Gua quantity) measurement

As seen in Table 1, while the 8-OH Gua/Gua quantities in the methyldopa group were determined to be of low significance ($p < 0.05$) compared to the healthy control group, of moderate significance in the rilmenidine group ($p < 0.001$), and of high significance in the clonidine and amlodipine groups ($p < 0.0001$), the increase in the 8-OH Gua/Gua quantities in the ramipril group was found to be insignificant ($p > 0.05$).

ALT, AST and LDH measurement

The ALT activities in the ramipril-administered group was determined to be of low significance ($p < 0.05$) compared to the healthy control group, and of very high significance in the other drug groups ($p < 0.0001$). The AST and LDH activities in the animal hepatic tissue receiving methyldopa, clonidine, rilmenidine, amlodipine and ramipril were very significant ($p < 0.0001$) compared to the healthy control group. These data have been presented in Figures 1-3.

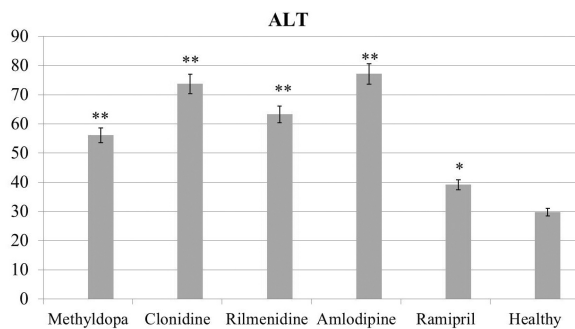


Figure 1. The ALT activities in methyldopa, clonidine, rilmenidine, amlodipine, ramipril and healthy control rat groups. Results are the means \pm standard error of the mean. *: $p < 0.05$; **: $p < 0.0001$.

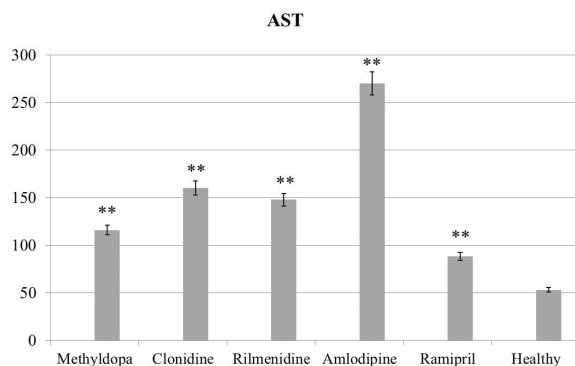


Figure 2. The AST activities in methyldopa, clonidine, rilmenidine, amlodipine, ramipril and healthy control rat groups. Results are the means \pm standard error of the mean. **: $p < 0.0001$.

LDH

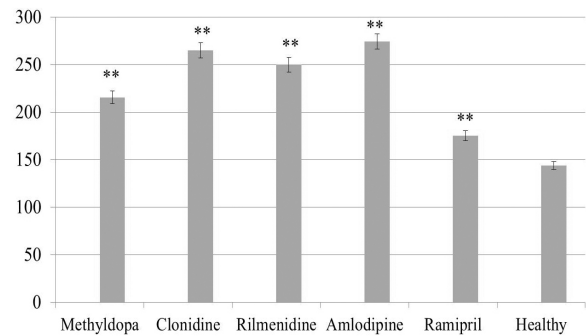


Figure 3. The LDH activities in methyldopa, clonidine, rilmenidine, amlodipine, ramipril and healthy control rat groups. Results are the means \pm standard error of the mean. **: $p < 0.0001$.

Pathological results

The microscopic examination results of the rat hepatic tissue receiving methyldopa, clonidine, rilmenidine, amlodipine and ramipril have been displayed in Table 2 and Figure 4.

The cell anatomy of the animal hepatic tissue of the healthy control group was microscopically normal in appearance, and no pathological findings were encountered. While there was observation of mildly condensed bile duct proliferation, mild portal inflammation, mild interface hepatitis and mild hepatocyte degeneration in the rat group receiving methyldopa, there was moderate focal necrosis. There were severe condensed bile duct proliferation, severe portal inflammation, severe interface hepatitis, severe focal necrosis and severe hepatocyte degeneration in the rat group receiving clonidine, in addition to moderate vascular abnormalities.

There were moderate condensed bile duct proliferation, moderate interface hepatitis and moderate vascular abnormalities in the rat group receiving rilmenidine, with observation of severe portal inflammation, severe focal necrosis and severe hepatocyte degeneration. Along with observation of moderate vascular abnormalities in the rat group receiving amlodipine, there were severe bile duct proliferation, severe portal inflammation, severe interface hepatitis, severe focal necrosis and severe hepatocyte degeneration. There was observation of moderate bile duct proliferation and moderate hepatocyte degeneration in the rat group receiving ramipril, there were also portal inflammation and mild interface hepatitis. There was no observation of focal necrosis or vascular abnormalities.

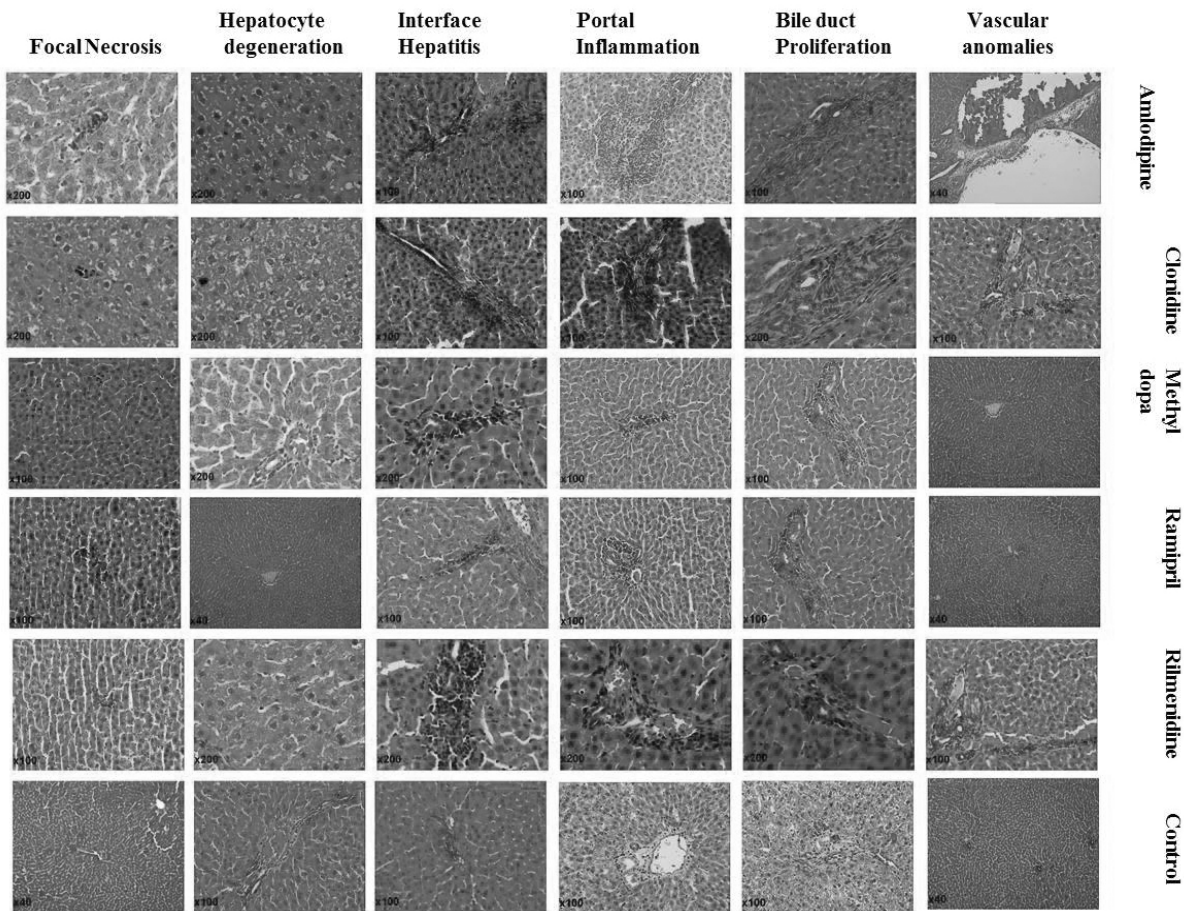


Figure 4. Microscopically examine results of the rat hepatic tissue given methyl dopa, clonidine, rilmenidine, amlodipine, ramipril and healthy control rat groups.

DISCUSSION

The biochemical and structural toxic effects in the hepatic tissue of rats receiving clonidine, methyl dopa, rilmenidine, amlodipine and ramipril over three months were studied in this trial and evaluated in comparison to each other. The experimental results showed that the drugs increasing the MDA quantity most in hepatic tissue were in the order of clonidine> amlodipine> rilmenidine> methyl dopa> ramipril.

MDA is the final product of lipid peroxidation. Lipid peroxidation is oxidative damage to poly-unsaturated fatty acids found in cell membranes caused by free radicals. This damage causes functional and structural disorders in cells. Furthermore, in some studies, these increased MDA levels have been correlated with increased lipid peroxidation due to the toxic effects of the disease and drugs ^{17,18}. In our study, the presence of high MDA quantities at different rates in animals receiving clonidine, methyl dopa, rilmenidine and amlodipine over a long period of time revealed that the toxic effects of

these drugs in the liver occurred at different rates. In the literature too, methyl dopa and clonidine have been shown to cause oxidative damage in the liver ^{19,20}.

Methyl dopa and clonidine bring about an antihypertensive effect through the same mechanism: stimulation of alpha-2 adrenergic receptors; despite the fact that the antihypertensive mechanisms of these drugs are the same, the levels of severity of the toxic effects on hepatic tissue were found to be different. Our experimental results have demonstrated that alpha-2 adrenergic receptors are not responsible for the hepatotoxic activities of methyl dopa and clonidine. Although rilmenidine inflicts more severe damage than the other two drugs, it is not a selective agonist of alpha-2 adrenergic receptors. Hence, there is no correlation between hepatotoxicity and alpha-2 adrenergic receptors. Likewise, amlodipine which has a higher toxic capacity than methyl dopa, is not related to the alpha-2 adrenergic receptor mechanism, suggesting that alpha-2 adrenergic receptors may have some

role in hepatotoxicity. James *et al.*²¹ reported that adrenalin had a hepatotoxic effect over alpha-2 adrenergic receptors and that this hepatotoxicity was exacerbated by clonidine, which is an alpha-2 adrenergic receptor agonist. In another study, the alpha-2 adrenergic receptors are reported being responsible from the antioxidant activity²².

In some studies, it was reported that intrahepatic canalicular cholestasis was seen in those using amlodipine²³. On the other hand, some studies, amlodipine has been shown as a hepatoprotective²⁴. In our experiment, the hepatotoxicity of amlodipine may have arisen from its use over a long period of time. Studies on angiotensin-converting enzyme drugs demonstrated that hepatotoxicity occurs in subjects receiving captopril, enalapril, lisinopril and fasinopril, and that no hepatotoxicity was encountered in those taking ramipril²⁵.

In our study, while methyldopa and ramipril only insignificantly increased the MPO activity in hepatic tissue, clonidine, rilmenidine and amlodipine significantly increased the MPO activity compared to the healthy control group. MPO is found in proinflammatory cells (PML). Activation of PMLs causes an over-release of superoxide, hydrogen peroxide and hydroxyl radicals, as well as MPO. The reaction of these radicals with MPO results in products such as hypochloric acid and N-chloramine, leading to tissue injury²⁶. Some antihypertensive drugs used in our study were seen to decrease the quantity of GSH, an endogenous antioxidant. GSH protects against oxidative injury and toxic components of cells. GSH, reacts with peroxides and free radicals and converts them into harmless products. GSH prevents -SH groups in protein from being oxidized by keeping them under reduction^{27,28}.

Free oxygen radicals cause the emergence of 8-hydroxyguanine (8-OH Gua), which is mutagenic when it reacts with DNA^{29,30}. 8-OH Gua has been accepted as an important indicator reflecting the oxidation of DNA³¹. Apart from ramipril, all drugs used in our study (methyldopa, clonidine, amlodipine, rilmenidine) significantly increased the 8-OH Gua quantity in the liver at different rates in comparison to the healthy control group. Studies on animals have demonstrated that the 8-OH Gua quantity increases in parallel with an increase in tissue injury⁹.

A significant increase was also demonstrated in the activities of AST, ALT, LDH, as well as the

oxidant parameters in hepatic injury³² AST, ALT and LDH are markers related with hepatocellular injury; ALT and AST are of special importance in determination of hepatic injury³³. One of the most trustworthy parameters is the ALT level, which demonstrates cell destruction in the liver³⁴. In this study, all the drugs used except ramipril, were found to significantly increase ALT at different rates.

Severe bile duct proliferation, portal inflammation, interface hepatitis, focal necrosis and hepatocyte degeneration were observed in the clonidine and amlodipine groups, which had higher oxidant parameters, higher AST, ALT, LDH activities and higher 8-OH Gua quantities. In those receiving rilmenidine, all the histopathological findings except bile duct proliferation and interface hepatitis were the same as those in the clonidine and amlodipine groups. The difference between ramipril and methyldopa was that bile duct proliferation and hepatocyte degeneration were more severe compared to the methyldopa group, and there was no focal necrosis. Bile duct proliferation, portal inflammation, interface hepatitis, focal necrosis, hepatocyte degeneration and vascular abnormalities³⁵⁻³⁸ develop in hepatic injury caused by oxygen radicals³⁹. Bile duct cell proliferation is seen in biliary obstruction⁴⁰. Slott *et al.*⁴¹ demonstrated that proliferation starts in bile duct epithelium cells in as short a time as 6 h after biliary obstruction. Severe portal inflammation and interface hepatitis were seen in the rat livers receiving all antihypertensive drugs except methyldopa and ramipril. The presence of inflammatory cells leads to cytolysis. Thus, focal loss of hepatocytes is defined as focal necrosis³⁵⁻³⁸. In our study, drugs other than methyldopa and ramipril were found to cause vascular injury at the level of the portal vein, hepatic artery, sinusoids and the central vein. This injury was seen in various forms namely sinusoidal dilatation, peliosis, veno-occlusive disease, hepatoportal sclerosis and intimal hyperplasia in the hepatic artery⁴².

As a result, these chemicals have been classified as inducers of biochemical and histopathological damage in the liver. The severity of damage by the drugs is as follows; mild (ramipril, methyldopa), moderate (rilmenidine) and severe (methyldopa, clonidine). The severity of drug-induced hepatotoxicity giving rise to increases in MDA, MPO tissues and DNA damage and decreases in GSH levels is seen to be parallel to the severity of hepatotoxicity.

REFERENCES

1. Wolf-Maier, K., R.S. Cooper, H. Kramer, J.R. Banegas, S. Giampaoli, M.R. Joffres *et al.* (2004) *Hypertension* **43**: 10-7.
2. Barnett, A.H. & P.M. Dodson (1997) *Hypertension and Diabetes*. London: Science Press.
3. Chobanian A.V., G.L. Bakris, H.R. Black, W.C.ushman, L.A. Green, J.L.Jr. Izzo *et al.* (2003) *J. Am. Med. Assoc.* **289**: 2560-72.
4. Black, H.R., W.J. Elliott, J.D. Neaton, G. Grandits, P. Grambsch, R.H.Jr. Grimm *et al.* (2001) *Hypertension* **37**: 12-8.
5. Cushman, W.C., C.E. Ford, J.A. Cutler, K.L. Margolis, B.R. Davis, R.H. Grimm *et al.* (2002) *J. Clin. Hypertens. (Greenwich)* **4**: 393-404.
6. Brunton, L.L. (2010) *Goodman and Gilman's The Pharmacological Basis of Therapeutics*. The McGraw-Hill Companies.
7. The sixth report of the Joint National Committee on prevention, detection, evaluation, and treatment of high blood pressure (1997) *Arch Intern Med.* **157**: 2413-46.
8. World Health Organization (1999) *J. Hypertens.* **17**: 151-83.
9. Polat, B., H. Suleyman & H.H. Alp (2010) *Chem. Biol. Interact.* **186**: 82-9.
10. Sedlak, J. & R.H. Lindsay (1968) *Anal. Biochem.* **25**: 192-205.
11. Bradley, P.P., D.A. Priebat, R.D. Christensen & G. Rothstein (1982) *J. Invest. Dermatol.* **78**: 206-9.
12. Ohkawa, H., N. Ohishi & K. Yagi (1979) *Anal. Biochem.* **95**: 351-8.
13. Shigenaga, M.K., E.N. Aboujaoude, Q. Chen & B.N. Ames (1994) *Meth. Enzymol.* **234**: 16-33.
14. Kaur, H. & B. Halliwell (1996) *Biochem. J.* **318**: 21-3.
15. Floyd, R.A., J.J. Watson, P.K. Wong, D.H. Alt-miller & R.C. Rickard (1986) *Free Radic. Res. Commun.* **1**: 163-72.
16. Asami, S., T. Hirano, R. Yamaguchi, Y. Tomio-ka, H. Itoh & H. Kasai (1996) *Cancer Res.* **56**: 2546-9.
17. Slatter, D.A., C.H. Bolton & A.J. Bailey (2000) *Diabetologia* **43**: 550-7.
18. Smathers, R.L., J.J. Galligan, B.J. Stewart & D.R. Petersen (2011) *Chem. Biol. Interact.* **192**: 107-12.
19. Costa, L.G., J. Gastel & S.D. Murphy (1991) *J. Toxicol. Environ. Health* **33**: 349-58.
20. Jones, D.P. (1981) *Res. Commun. Chem. Pathol. Pharmacol.* **33**: 215-22.
21. James, R.C., S.M. Roberts & R.D. Harbison (1983) *Fundam. Appl. Toxicol.* **3**: 303-8.
22. Suleyman, H. (2012) *Eurasian J. Med.* **44**: 43-5.
23. Zinsser, P., B. Meyer-Wyss & P. Rich (2004) *Swiss Med. Wkly.* **134**: 201.
24. Dursun, H., F. Albayrak, A. Uyanik, N.O. Ke-les, P. Beyzagul, E. Bayram *et al.* (2010) *Turk. J. Gastroenterol.* **21**: 387-95.
25. Yeung, E., F.S. Wong, I.R. Wanless, K. Shiota, M. Guindi, S. Joshi *et al.* (2003) *Arch. Pathol. Lab. Med.* **127**: 1493-7.
26. Karmeli, F., E. Okon & D. Rachmilewitz (1996) *Gut.* **38**: 826-31.
27. Meister, A. (1991) *Pharmacol. Therapeut.* **51**: 155-94.
28. Urso, M.L. & P.M. Clarkson (2003) *Toxicology* **189**: 41-54.
29. Huang, H.E., K.J. Helzlsouer & L.J. Appel (2000) *Cancer Epidem. Biomar.* **9**: 647-52.
30. Marnett, L.J. (2000) *Carcinogenesis* **21**: 361-70.
31. Grollman, A.P. & M. Moriya (1993) *Trends Genet.* **9**: 246-9.
32. Sutcu, R., I. Altuntas, B. Yildirim, N. Karahan, H. Demirin & N. Delibas (2006) *Cell Biol. Toxicol.* **22**: 221-7.
33. Li, Y.M., S.H. Chen, C.H. Yu, Y. Zhang & G.Y. Xu (2004) *Hepatob. Pancreat. Dis. Int.* **3**: 241-4.
34. Hamanoue, M., K. Kawaida, S. Takao, H. Shi-mazu, S. Noji, K. Matsumoto *et al.* (1992) *Hepatology.* **16**: 1485-92.
35. Broulac-Sage, P. & C. Balabaud (2004) *Toxic and drug induced disorders of the liver*. Philadelphia: Saunders.
36. Lee, R. (1994) *Diagnostic liver pathology*. Vol 1. St Louis: Mosby.
37. Scheuer, P. (1988) *Liver biopsy interpretation*. Vol 4. Philadelphia: W.B. Saunders.
38. Zimmerman, H.J. & K.G. Ishak (2002) *Pathology of the liver*. Vol 14. 4th Ed. Philadelphia: Churchill Livingstone.
39. Boll, M., L.W. Weber, E. Becker & A. Stampfl (2001) *Z. Naturforsch. C.* **56**: 649-59.
40. Randall, G. & M.D. Lee (1994) *Diagnostik liver pathology* (eds.): Mosby Company.
41. Slott, P.A., M.H. Liu & N. Tavoloni (1990) *Gastroenterology* **99**: 466-77.
42. Kaplowitz, N. (2004) *Clin. Infect. Dis.* **38**: 44-8.