



# High-resolution diffusion-weighted imaging compared with conventional diffusion-weighted imaging and dynamic contrast-enhanced magnetic resonance imaging with regard to image quality and assessment of breast cancer morphology

Yavuz Metin   
Nurgül Orhan Metin   
Sibel Kul   
Filiz Taşçı   
Oğuzhan Özdemir   
Ali Küpeli 

From the Department of Radiology (Y.M. ✉ ymetin53@gmail.com), Ankara University Faculty of Medicine, Ankara, Turkey; Clinic of Radiology (N.O.M.), Beytepe Murat Erdi Eker State Hospital, Ankara, Turkey; Department of Radiology (S.K.), Karadeniz Technical University Faculty of Medicine, Trabzon, Turkey; Department of Radiology (F.T.), Recep Tayyip Erdoğan University Faculty of Medicine, Rize, Turkey; Clinic of Radiology (O.Ö.), Keçiören Medical Park Hospital, Ankara, Turkey; Clinic of Radiology (A.K.), Trabzon Kanuni Training and Research Hospital, Trabzon, Turkey

Received 24 April 2021; revision requested 28 May 2021; last revision received 29 November 2021; accepted 30 December 2021.



Epub: 10.02.2023

Publication date: 29.03.2023

DOI: 10.5152/dir.2022.21362

## PURPOSE

To evaluate the image quality and tumor morphology depiction ability of high resolution (HR) diffusion-weighted imaging (f-DWI) in comparison to conventional DWI (c-DWI) and dynamic contrast-enhanced magnetic resonance imaging (DCE-MRI) in the primary breast cancer setting.

## METHODS

The f-DWI, c-DWI, and DCE-MRIs of 160 malignant breast masses were evaluated retrospectively by two independent radiologists. Data on image quality [sharpness, distortion, and perceived signal-to-noise ratio (SNR)], apparent diffusion coefficient (ADC) value, lesion size, and tumor morphology (shape, margin, and internal pattern) obtained on f-DWI, c-DWI, and DCE-MRI were compared. Consistency between the readers and imaging methods for morphological parameters was analyzed.

## RESULTS

The ADC values measured on f-DWI were significantly lower than those measured on c-DWI for both readers ( $P < 0.001$  for each), whereas mean lesion size was significantly larger in c-DWI than in f-DWI and DCE-MRI for both readers ( $P < 0.001$  for each). Higher consistency values were obtained for f-DWI compared with c-DWI when correlated with DCE-MRI for each morphological parameter. The least distorted images were obtained using DCE-MRI compared with c-DWI and f-DWI for both readers, whereas the highest distortion scores were obtained using c-DWI. Sharpness and perceived SNR scores were rated as significantly higher for f-DWI and DCE-MRI images compared with c-DWI by both readers ( $P < 0.001$  for all). The concordance between c-DWI and DCE-MRI was fair to slight ( $\kappa = 0.15$  to  $0.41$ ), whereas concordance between f-DWI and DCE-MRI was significantly better ( $\kappa = 0.68$  to  $0.87$ ) for each reader and for all morphological parameters ( $P < 0.001$ ). The highest concordance between the readers was achieved in margin assessment ( $\kappa = 0.87$  to  $0.89$ ) regardless of the MRI method, followed by shape and internal pattern parameters ( $\kappa = 0.63$  to  $0.79$ ).

## CONCLUSION

The results demonstrated that f-DWI produces higher-quality images than c-DWI, enabling the morphological features to be identified in similar detail to that offered by HR DCE-MRI. Accordingly, f-DWI, as a method that highly correlates with DCE in determining the morphological characteristics of breast cancers, seems to have potential in the evaluation of breast tumors in patients for whom the use of contrast media is contraindicated.

## KEYWORDS

Breast cancer, conventional, high resolution diffusion weighted, magnetic resonance imaging, tumor morphology

You may cite this article as: Metin Y, Orhan Metin N, Kul S, Taşçı F, Özdemir O, Küpeli A. High-resolution diffusion-weighted imaging compared with conventional diffusion-weighted imaging and dynamic contrast-enhanced magnetic resonance imaging with regard to image quality and assessment of breast cancer morphology. *Diagn Interv Radiol.* 2023;29(2):251-259.

**M**agnetic resonance imaging (MRI) techniques have become increasingly used as the preferred imaging modality for the diagnosis, staging, and follow-up of breast cancer.<sup>1,2</sup> Dynamic contrast-enhanced (DCE) MRI series are routinely used because of their high contrast and spatial resolution; however, contrast agent-related side effects or contraindications such as renal insufficiency or known allergic reactions are the major drawbacks of this technique.<sup>3,4</sup> Diffusion-weighted imaging (DWI), a non-contrast-MRI method based on the production of images from the random Brownian motion of water molecules, is considered highly effective in the differential diagnosis of breast tumors and is commonly applied as an adjunct to DCE-MRI for breast imaging.<sup>5,6</sup>

Conventional DWI (c-DWI), applied using single-shot echo-planar imaging (ss-EPI) in most cases, is considered favorable because of its speed. However, low spatial resolution; the high frequency of distortion, blurring, and artifacts; and low signal-to-noise ratio (SNR) are some of the major disadvantages of this technique.<sup>7,8</sup> With recent technological advances, high-resolution (HR) DWI has become a popular method with its increased spatial resolution and reduction in artifacts and distortions, compared with c-DWI.<sup>9-11</sup>

One of the improved HR-DWI approaches is to implement a reduced field-of-view (rFOV) acquisition. This is a technique called focus DWI (f-DWI), which aims to shorten the required readout duration for ss-EPI.<sup>2,12,13</sup> The manner in f-DWI differs from other rFOV techniques in terms of active excitation of the imaging region of interest (ROI) itself, which does not necessitate outer-volume suppression pulses, with a likelihood of potentially higher specific absorption rates.<sup>14</sup> In contrast to inner-volume methods, this technique allows contiguous multislice imaging without

the need for a slice skip<sup>15</sup> and concomitantly suppresses the signal from fat, which is considered to be important in breast imaging.<sup>2</sup>

Although HR-DWI is mainly used in the field of neuroradiology, its importance in breast imaging has also been emphasized in recent years.<sup>9-11</sup> In breast imaging, c-DWI has mainly been used for the quantitative evaluation [determination of apparent diffusion coefficient (ADC) values] of breast lesions. However, obtaining high-quality images using HR-DWI demonstrated that DWIs can also be used qualitatively, such as for determining tumor morphology. In this context, there are a few publications comparing the compatibility of HR-DWI with c-DWI and DCE-MRI in determining the morphological features of breast lesions. However, in these studies, conducted with small numbers of patients, the aim was to compare the image quality rather than evaluate the morphological features in detail.<sup>2,11,16-20</sup>

In this study with the participation of a large number of patients with breast cancer, the aim was to compare f-DWI with both c-DWI and DCE-MRI in characterizing all morphological features (shape, margin, internal pattern, and size) of the tumor and in terms of image quality.

## Methods

### Study population

A total of 175 patients who had undergone breast MRI, including both f-DWI and c-DWI, using a 3T MRI scanner and who had a pathologically proven breast cancer diagnosis were included in this retrospective study conducted between November 2014 and September 2017. Patients with available data on three methods (f-DWI, c-DWI, and DCE-MRI) of imaging with sufficient image quality were included in the study. Non-mass enhancement, focus-type lesions, cysts, concomitant neoadjuvant chemotherapy, and insufficient image quality were the exclusion criteria of the study. After the exclusion of 11 patients in the c-DWI group, 5 patients in the f-DWI group, and 4 patients in the DCE-MRI group upon detection of motion artifacts affecting image quality, a total of 155 consecutive patients with 160 breast tumors comprised the study population.

The ethics committee of our university hospital approved this study (date of approval: 16/06/2017; reference number/protocol no: 2017/96). Informed consent was waived due to the retrospective design of the study.

### Study parameters

Data on ADC values ( $10^{-3}$  mm<sup>2</sup>/s), lesion size (mm), tumor morphology (shape, margin, and internal pattern), image quality (sharpness, distortion, and perceived SNR) obtained using f-DWI, c-DWI, and DCE-MRI were compared. Consistency analyses between the two DWI methods and DCE-MRI were performed for both morphological parameters and image quality. Interobserver agreement was also analyzed.

### Magnetic resonance imaging methods

MRI scanning was performed using a 3.0-T MR (GE Healthcare Discovery MR750, Waukesha, WI, USA) together with a 16-channel dedicated breast coil. Patients lay in a prone position, with the breasts inside the breast coil. A survey sequence was followed by axial T1-weighted (T1W) sequence and fat-saturated T2-weighted (T2W) fast spin-echo sequence for both breasts prior to contrast administration to avoid signal alteration as a result of the injected gadolinium. For DCE-MRI, the contrast agent gadobutrol (Gadovist, Bayer Schering Pharma, Berlin, Germany) was injected (0.1 mmol/kg bolus injection, flow rate of 2 mL/s), and then the residual contrast agent in the catheter was rinsed with 20 mL of saline at the same rate. After the injection, six phases of volume imaging for breast assessment (VIBRANT-Flex) were employed, with approximately 60-s intervals between each phase and a total scanning of 410 s [repetition time (TR) 3.9 ms, shortest echo time TE, flip angle 12, FOV 360–360 mm, matrix 320–320, layer thickness 1.4 mm].

Subsequently, c-DWI and then f-DWI were performed before the contrast injection by using the same b-values (0–800 s/mm<sup>2</sup>). The target for f-DWI was determined by reviewing the clinical and conventional imaging findings and with the assistance of non-contrast MRI (axial fat-saturated T2W and T1W images). A combined sequence using the array spatial sensitivity encoding technique was conducted prior to scanning. The scanning parameters of c-DWI and f-DWI were a TR of 3600 ms, FOV of 360–360 mm, matrix of 160–160 of matrix, shortest TE, 1 mm gap, 4 mm slice thickness, bandwidth of 250, and 6 excitations. The scanning time was 76 s for c-DWI and 164 s for f-DWI.

### Morphological analysis

All MR images were reviewed retrospectively by two dedicated breast radiologists (YM and NOM, who had 6-years' and 4-years'

#### Main points

- In determining the morphological characteristics of primary breast cancer, high-resolution (HR) diffusion-weighted imaging (f-DWI) shows good consistency with dynamic contrast-enhanced magnetic resonance imaging and is superior to conventional DWI (c-DWI).
- Having less distortion and obtaining a higher perceived signal-to-noise ratio and sharpness significantly increases the image quality of f-DWI images compared with c-DWI.
- High-quality images obtained with f-DWI will positively increase the problem-solving ability of c-DWI, especially in situations where contrast material cannot be used.

experience of breast imaging, respectively) blinded to the clinical history and other primary imaging findings. The radiologists independently evaluated the morphological features of the masses in separate sessions for f-DWI, c-DWI, and DCE-MRI at 3-week intervals on a GE Healthcare workstation (ADW 4.5, GE Healthcare, Waukesha, WI, USA). The shape, margin, and internal pattern of each case were evaluated on high *b* value (800 s/mm<sup>2</sup>) f-DWI and c-DWI images and on subtracted and non-subtracted DCE-MR images obtained in the second minute postcontrast. Morphological descriptors defined in the fifth edition of the American College of Radiology Breast Imaging Reporting and Data System (BI-RADS)<sup>21</sup> were used. Accordingly, the shapes of the masses were categorized as round, oval, and irregular. The margins of the masses were categorized as circumscribed and non-circumscribed, and the internal patterns of the masses were categorized as homogeneous, heterogeneous, and rim type. The internal enhancement pattern was arranged as an internal pattern to be compatible with DWI, which is an unenhanced imaging method. The ADC values on the DWIs and the longest diameter of the masses on the axial slices in each imaging method (high *b* values of DWIs and subtracted postcontrast 2<sup>nd</sup> minute images of DCE) were measured. The ADC measurement was performed by placing circular ROIs within the targeted lesion on ADC maps. The portion of the lesion showing the most diffusion restriction was determined visually, and the mean ADC measurements were performed from this area. A

circular ROI was placed inside the lesion and made as large as possible while avoiding cystic, necrotic or hemorrhagic areas and obvious artifacts. The ROI size was set at ≥2 cm<sup>2</sup>. For each lesion, at least three measurements were taken, and the lowest value was used.

### Analysis of image quality

After the analysis of the morphological features of the breast tumors, another session was organized to evaluate the quality of the f-DWI, c-DWI, and DCE-MR images. Both readers independently evaluated all imaging methods simultaneously. Image quality was evaluated in three categories: sharpness (5 point scale: 1 = unsharp to 5 = very sharp), distortion (4-point scale: 0 = no distortion to 3 = severe distortion), and perceived SNR (5-point scale: 1 = very poor to 5 = excellent).

### Statistical analysis

Statistical analysis was performed using SPSS 15.0 software (SPSS Inc., Chicago, IL, USA) and the MedCalc package (version 16.8, Ostend, Belgium). Descriptive statistics of the data are presented as n (%). Non-normalized variables are presented as median (range), and normal distributions are presented as mean ± standard deviation. The Kolmogorov–Smirnov test was used to show deviation from the normal distribution. The non-parametric Wilcoxon test (Table 1) was used by each reader to compare the ADC values obtained in c-DWI and f-DWI. A paired t-test (Table 2) was used to compare lesion size measured on f-DWI and DCE-MRI with lesion size measured on c-DWI for the same reader.

The Friedman test with the Bonferroni correction was used to compare the sharpness, distortion, and perceived SNR scores (categorized in Table 3; the readers rated image quality on point scales) measured on f-DWI, c-DWI, and DCE-MRI by the same reader. The Wilcoxon test was used for pairwise comparisons. Agreement between methods and readers was evaluated using Cohen's kappa coefficients and intraclass correlation (ICC), and expressed using kappa and ICC values, with 0.81–1.00, 0.61–0.80, 0.41–0.60, 0.21–0.40, and 0.10–0.20 indicating a very good, good, moderate, fair, and slight strength of agreement, respectively.<sup>22,23</sup> *P* < 0.05 was considered significant.

## Results

In the current study, 160 malignant breast mass lesions (multifocal tumors in four patients and bilateral breast cancer in one patient) were evaluated, including invasive ductal carcinoma with no special type (*n* = 135), invasive lobular carcinoma (*n* = 9), mucinous carcinoma (*n* = 8), ductal carcinoma *in situ* (*n* = 3), malignant phyllodes tumor (*n* = 2), medullary carcinoma (*n* = 2), and tubular carcinoma (*n* = 1). The median age of the patients was 52 years (range 17–87 years).

### Breast lesion characteristics on imaging analysis

The ADC values measured on f-DWI were significantly lower than those measured on c-DWI for both readers (*P* < 0.001) (Table 1).

The tumor shape was considered to be

**Table 1.** Breast tumor characteristics on c-DWI, f-DWI, and DCE-MRI

	Reader 1			Reader 2		
	c-DWI	f-DWI	DCE-MRI	c-DWI	f-DWI	DCE-MRI
ADC (x10 <sup>-3</sup> mm <sup>2</sup> /s), median (range)	0.95 (0.55–1.97)	0.83 (0.24–1.82)	-	0.93 (0.55–1.90)	0.88 (0.24–1.87)	-
<i>P</i> value of ADC	<0.001			<0.001		
<b>Tumor morphology, n (%)</b>						
<b>Shape</b>						
Round	54 (33.75)	16 (10.00)	13 (8.12)	52 (32.50)	31 (19.38)	27 (16.88)
Oval	37 (23.12)	18 (11.25)	26 (16.25)	26 (16.25)	21 (13.12)	21 (13.12)
Irregular	69 (43.13)	126 (78.75)	121 (75.63)	82 (51.25)	108 (67.50)	112 (70.00)
<b>Margin</b>						
Circumscribed	92 (57.50)	47 (29.37)	52 (32.50)	100 (62.50)	68 (42.50)	60 (37.50)
Non-circumscribed	68 (42.50)	113 (70.63)	108 (67.50)	60 (37.50)	92 (57.50)	100 (62.50)
<b>Internal pattern</b>						
Homogeneous	93 (58.13)	24 (15.00)	20 (12.50)	82 (51.25)	45 (28.12)	48 (30.00)
Heterogeneous	37 (23.12)	56 (35.00)	60 (37.50)	50 (31.25)	64 (40.00)	67 (41.88)
Rim type	30 (18.75)	80 (50.00)	80 (50.00)	28 (17.50)	51 (31.88)	45 (28.12)

c-DWI, conventional diffusion-weighted imaging; f-DWI, focus diffusion-weighted imaging; DCE-MRI, dynamic contrast-enhanced magnetic resonance imaging; ADC, apparent diffusion coefficient.

irregular in most cases regardless of the MRI method; however, the tumor margin was defined as circumscribed in c-DWIs (57.50% of cases for reader 1; 62.50% of cases for reader 2) and non-circumscribed in f-DWI (70.63%

of cases for reader 1; 57.50% of cases for reader 2) and DCE-MRI (67.50% of cases for reader 1; 62.50% of cases for reader 2) by both readers. The tumor internal pattern was defined as homogeneous in c-DWI by both

readers (58.13% of cases for reader 1; 51.25% of cases for reader 2), whereas reader 1 defined it as rim type (50% of cases with both methods) and reader 2 as heterogeneous in f-DWI (40% of cases) and DCE-MRI (41.88% of

**Table 2.** Comparison of lesion dimensions (mm) of c-DW with f-DW and DCE-MRI

	Reader 1			Reader 2		
	f-DWI	c-DWI	DCE-MRI	f-DWI	c-DWI	DCE-MRI
mean ± SD	27 ± 16	28 ± 17	27 ± 16	27 ± 16	28 ± 17	27 ± 15
P value		<0.001			<0.001	

c-DWI, conventional diffusion-weighted imaging; f-DWI, focus diffusion-weighted imaging; DCE-MRI, dynamic contrast-enhanced magnetic resonance imaging; SD, standard deviation.

**Table 3.** Frequencies of image quality analysis scores on c-DWI, f-DWI, and DCE-MRI images

	Reader 1			Reader 2		
	c-DWI	f-DWI	DCE-MRI	c-DWI	f-DWI	DCE-MRI
<b>Image quality, n (%)</b>						
<b>Sharpness</b>						
Median (range)	3 (1–5)	5 (3–5)	5 (4–5)	4 (1–5)	5 (3–5)	5 (4–5)
1 = unsharp	1 (1%)	-	-	1 (1%)	-	-
2 = somewhat unsharp	25 (16%)	-	-	18 (11%)	-	-
3 = moderately sharp	63 (39%)	9 (6%)	-	65 (40%)	8 (5%)	-
4 = sharp	62 (38%)	60 (37%)	32 (20%)	67 (42%)	51 (32%)	32 (20%)
5 = very sharp	9 (6%)	91 (57%)	128 (80%)	9 (6%)	101 (63%)	128 (80%)
P value		<0.001			<0.001	
P value (sharp dw-sharp focus)		<0.001			<0.001	
P value (sharp dw-sharp c)		<0.001			<0.001	
P value (sharp focus-sharp c)		0.013			0.082	
<b>Distortions</b>						
Median (range)	2 (0–3)	0 (0–2)	0 (0–1)	2 (0–3)	1 (0–2)	0 (0–1)
0 = no distortions	25 (16%)	77 (48%)	142 (89%)	24 (15%)	75 (47%)	139 (87%)
1 = some, interpretable	58 (35%)	76 (47%)	18 (11%)	58 (36%)	77 (48%)	21 (13%)
2 = severe, interpretable	68 (43%)	7 (5%)	-	69 (43%)	8 (5%)	-
3 = severe, uninterpretable	9 (6%)	-	-	9 (6%)	-	-
P value		<0.001			<0.001	
P value (sharp dw-sharp focus)		<0.001			<0.001	
P value (sharp dw-sharp c)		<0.001			<0.001	
P value (sharp focus-sharp c)		<0.001			<0.001	
<b>Perceived SNR</b>						
Median (range)	4 (1–5)	5 (3–5)	5 (3–5)	4 (1–5)	5 (3–5)	5 (3–5)
1 = very poor	2 (1%)	-	-	2 (1%)	-	-
2 = poor	21 (13%)	-	-	19 (12%)	-	-
3 = acceptable	56 (35%)	4 (3%)	1 (1%)	56 (35%)	3 (2%)	1 (1%)
4 = good	66 (42%)	59 (37%)	31 (19%)	68 (42%)	57 (36%)	28 (17%)
5 = excellent	15 (9%)	97 (60%)	128 (80%)	15 (9%)	100 (62%)	131 (82%)
P value		<0.001			<0.001	
P value (sharp dw-sharp focus)		<0.001			<0.001	
P value (sharp dw-sharp c)		<0.001			<0.001	
P value (sharp focus-sharp c)		0.088			0.108	

Bonferroni correction adjusted P value was 0.0167 for Table 3. c-DWI, conventional diffusion-weighted imaging; f-DWI, focus diffusion-weighted imaging; DCE-MRI, dynamic contrast-enhanced magnetic resonance imaging; SNR, signal-to-noise ratio.

cases) (Table 1).

The mean lesion size was significantly larger in c-DWI than in f-DWI and DCE-MRI for both readers ( $P < 0.001$ ) (Table 2).

### Image quality analysis

The findings on image quality analysis based on each method are provided in Table 3. The quality analysis on c-DWI demonstrated that 12%–16% of images were unsharp, a total of 5% of images were uninterpretable due to distortions, and 13%–14% of cases had poor perceived SNR. However, unsharp, uninterpretable due to severe distortion, and poorly perceived SNR images were not detected in f-DWI and DCE-MRI (Table 3).

The least distorted images were obtained in DCE-MRI for both readers, whereas the highest distortion scores were obtained in c-DWI (Table 3, Figure 1). Sharpness and perceived SNR scores were rated as significantly higher for f-DWI and DCE-MRI images than for c-DWI by both readers ( $P < 0.001$  for all). No significant difference was noted between f-DWI and DCE-MRI in terms of sharpness and perceived SNR scores for both readers (for reader 1,  $P = 0.083$  and  $P = 0.157$ , and for reader 2,  $P = 0.059$  and  $P = 0.102$ , respectively) (Table 3). However, when f-DWI and DCE-MRI were compared in terms of distortion scores, it was found that both readers determined statistically lower distortion scores for DCE-MR images than for f-DWIs ( $P < 0.001$ ).

When the interreader agreement was evaluated in terms of image quality, excellent agreement was found for sharpness (ICC: 0.95, 0.97, and 0.94;  $P < 0.001$ ), distortion (ICC: 0.98, 0.99, and 0.95;  $P < 0.001$ ), and perceived SNR scores (ICC: 0.98, 0.99, and 0.97;  $P < 0.001$ ) for f-DWI, c-DWI, and DCE-MRI, respectively.

### Consistency of diffusion-weighted imaging methods with dynamic contrast-enhanced magnetic resonance imaging in terms of tumor morphology

Because of their high spatial resolution, contrast-enhanced series are the images most commonly chosen for determining the morphological features of breast tumors, and thus consistency analyses were performed between DCE-MRI and both DWIs. In evaluations made independently of lesion size, consistency between f-DWI and DCE-MRI was significantly better ( $\kappa$  value range between 0.68 and 0.87 for reader 1 and between 0.72 and 0.80 for reader 2) compared with the consistency between c-DWI and DCE-MRI ( $\kappa$

value range between 0.15 and 0.24 for reader 1 and between 0.23 and 0.46 for reader 2) for all parameters (shape, margin, and internal pattern) ( $P < 0.001$  for both readers) (Table 4).

Based on the measurements made by reader 1 (the more experienced radiologist) in DCE-MRI, when the sizes of the lesions were grouped into three main groups, 36 (22%) of the lesions were  $< 15$  mm (group 1), 56 (35%) were between 16 and 25 mm (group 2), and the remaining 68 (43%) were  $> 25$  mm (group 3). According to this classification, in determining the tumor shape, concordance between DCE-MRI and DWIs increased with increasing lesion size for both readers (for reader 1,  $\kappa = 0.06, 0.20,$  and  $0.23$ , and for reader 2,  $\kappa = 0.23, 0.37,$  and  $0.41$  on c-DWI; for reader 1,  $\kappa = 0.77, 0.82,$  and  $0.93$ , and for reader 2,  $\kappa = 0.72, 0.73,$  and  $0.94$  on f-DWI; respectively;  $P < 0.001$  for both readers). Similarly, the consistency in the determination of lesion margins increased with increasing lesion size (for reader 1,  $\kappa = 0.13,$

0.17, and 0.20 and  $\kappa = 0.12, 0.22,$  and  $0.25$  on c-DWI; for reader 2,  $\kappa = 0.70, 0.77,$  and  $0.90$  and  $\kappa = 0.71, 0.77,$  and  $0.86$  on f-DWI, respectively;  $P < 0.001$  for both readers). When the compatibility in the determination of tumor internal patterns was evaluated, an increase was found in c-DWIs for both readers as the tumor size increased (for reader 1,  $\kappa = 0.09, 0.12,$  and  $0.27,$  and for reader 2,  $\kappa = 0.12, 0.15,$  and  $0.38,$  respectively) ( $P < 0.001$  for both readers). In f-DWI, the highest agreement was found in tumors ranging from 16 to 25 mm (for reader 1,  $\kappa = 0.62, 0.76,$  and  $0.55$  and for reader 2,  $\kappa = 0.64, 0.77,$  and  $0.64,$  respectively;  $P < 0.001$  for both readers) (Table 5).

### Interobserver agreement in assessing tumor morphology

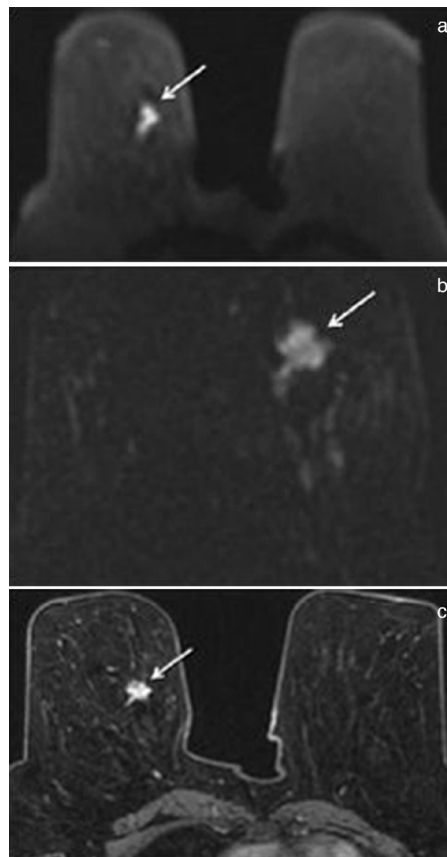
Considering the interobserver agreement, the highest concordance between readers was achieved in assessing the margin parameter ( $\kappa = 0.87$  to  $0.89$ ;  $P < 0.001$ ) regardless of the MRI method, followed by shape and internal pattern parameters ( $\kappa = 0.63$  to  $0.79$ ;  $P < 0.001$ ). However, higher interobserver agreement values were obtained for c-DWI, particularly for shape and internal pattern ( $P < 0.001$  for each) (Table 6, Figures 2, 3).

## Discussion

Our findings revealed that f-DWI shows good consistency with DCE-MRI and is superior to c-DWI in assessing tumor morphology in primary breast cancer settings. Thus, even in cases where contrast material cannot be used, it will be possible to evaluate tumor morphology and size in a more detailed and clearer manner in a short time, with higher quality, less distortion, higher perceived SNR, and greater sharpness on HR-DWI. It is thought that employing f-DWI together with c-DWI will be of great benefit for increasing diagnostic accuracy.

As a HR imaging technique, DCE-MRI provides information about enhancement patterns of breast lesions and a detailed assessment of tumor morphology, allowing these lesions to be categorized accurately in the BI-RADS classification.<sup>24</sup> In fact, in a study by Goto et al.<sup>25</sup>, breast lesions were reported as likely to be diagnosed as benign and malignant based on only morphological assessment, regardless of the kinetic enhancement patterns obtained on DCE-MRI.

However, contrast-enhanced series cannot be obtained in the presence of a known contrast material allergy or renal dysfunction. In these cases, the importance and use of unenhanced series increases. In c-DWI, which



**Figure 1.** A 58-year-old female patient with a diagnosis of invasive ductal cancer in the lower outer quadrant of the right breast is observed. In conventional diffusion-weighted image (a), the marginal feature of the lesion is difficult to identify due to distortion. Due to HR in focus diffusion-weighted (b) and dynamic contrast-enhanced imaging (c), the marginal features of the lesion can be determined more clearly.

is one of the preferred unenhanced MRI methods, we attempted to obtain information about the quantitative values of breast lesions rather than their qualitative characteristics.<sup>26,27</sup> However, in recent years, there have been various publications investigating the diagnostic contribution of DWIs in determining the morphological features of breast lesions.<sup>16,17,19,20,28</sup> Kang et al.<sup>16</sup> highlighted the potential utility of c-DWI in assessing morphological features of lesions with high accuracy rates, which can be used for benign-malignant differentiation or for prognostic predictions. We have also previously reported the favorable utility of c-DWI in assessing the size and morphology of breast masses, along with a good consistency between c-DWI and DCE-MRI.<sup>17</sup> In addition, Radovic et al.<sup>19</sup> conducted a comparison of DCE-MRI

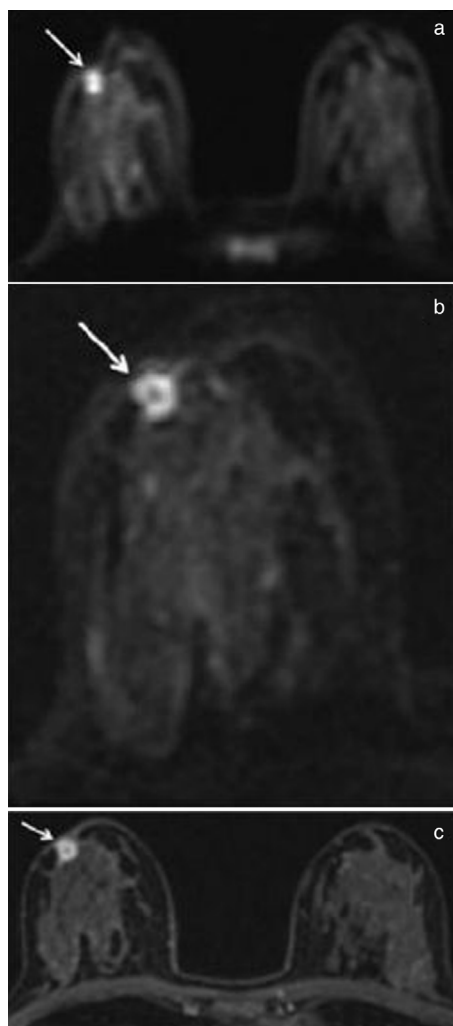
and c-DWI to evaluate the morphological features of breast lesions, reporting the presence of a moderate-to-substantial consistency between c-DWI and DCE-MRI along with similar values of interobserver agreement for each method. If the morphological features of breast masses could be obtained accurately using DWI, as in DCE-MRI, based on BI-RADS descriptors, this information could be used in the further characterization of breast masses and the prognostication and prediction of the response to breast cancer treatment using an unenhanced MRI method.

Despite all these data, the key reason why c-DWI is still less desirable than DCE-MRI in the qualitative evaluation of breast lesions is because it has disadvantages, such as low SNR, low resolution, and relatively low-quality images caused by magnetic susceptibility and chemical shift artifacts.

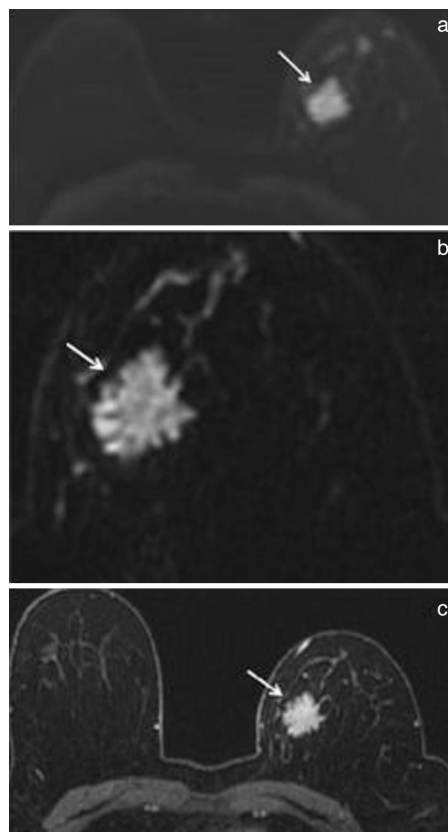
HR-DWI is a new technique developed to increase diagnostic accuracy, both quantitatively and qualitatively, by minimizing the disadvantages of experience in c-DWI.<sup>2</sup> In the literature, there are studies showing

that HR-DWI provides higher-quality images than c-DWI and is a more effective method for categorizing breast lesions according to the BI-RADS classification and also for determining their morphological features. Similarly, it has been reported that HR-DWI is more compatible with DCE-MRI in determining the qualitative characteristics of breast lesions compared with c-DWI. For example, in a previous study by Dong et al.<sup>29</sup> comparing rFOV DWI and c-DWI of breast tissue, rFOV DWI was reported to be associated with a significantly higher image quality score and higher resolution. The authors also considered rFOV DWI to be a potentially helpful technique in the diagnosis of breast cancer. Again, in a study using readout-segmented EPI, another HR-DWI method,<sup>30</sup> it was reported that obtaining higher-quality images compared with c-DWI is convenient and contributes greatly to the identification of breast tumors and the determination of their morphological features. In another study, Kishimoto et al.<sup>20</sup> reported a high agreement between HR-DWI and DCE-MRI in the assessment of morphological features and extent of malignant breast lesions. This study concluded that HR-DWIs can improve the diagnostic accuracy of unenhanced MRI. Barentsz et al.<sup>18</sup> reported that HR-DWI provided greater sharpness and perceived SNR than c-DWI, and as a result, the BI-RADS classification of breast lesions was achieved more accurately. By contrast, in the present study, with the participation of more patients, not only the shape features of the breast lesions but also the margin and internal pattern features were evaluated. As a result of our study, consistent with the findings of Barentsz et al.<sup>18</sup>, we determined that all breast lesion morphological features could be determined in detail, similar to contrast-enhanced series, with f-DWI providing higher-quality images.

One of the key results of our study is that although the best agreement among readers in determining tumor morphology was obtained for c-DWI, better agreement was found between f-DWI and DCE-MRI when the consistency between the methods was examined. This is mainly due to the fact that f-DWI provides high-quality images, which reveals tumor morphology more clearly and results in higher intermethod agreement with DCE-MRI. However, the fact that images with less clarity were obtained with c-DWIs compared with f-DWIs meant the readers were able to determine the morphological features in detail, resulting in better interobserver compatibility. Thus, it is thought that high-quality images obtained in f-DWIs



**Figure 2.** A 46-year-old female patient with a diagnosis of invasive ductal cancer in the retroareolar area of the right breast. Conventional diffusion-weighted image (a) showed homogeneous diffusion restriction in the lesion. Focus diffusion-weighted image (b) showed ring-shaped diffusion restriction in the lesion. In dynamic contrast-enhanced image (c), there is a circular pattern of enhancement in the lesion.



**Figure 3.** A 75-year-old female patient with a diagnosis of invasive ductal cancer in the upper inner quadrant of the left breast is observed. In conventional diffusion-weighted image (a), the shape of the mass was evaluated as lobulated. Focus diffusion-weighted (b) and dynamic contrast-enhanced images (c) revealed irregular shape of the lesion.

**Table 4.** Intermethod agreement for assessment of tumor morphology

		Reader 1		Reader 2	
		Kappa	P value	Kappa	P value
<b>Shape</b>	c-DWI and DCE-MRI	0.24	<0.001	0.41	<0.001
	f-DWI and DCE-MRI	0.87	<0.001	0.78	<0.001
<b>Margin</b>	c-DWI and DCE-MRI	0.22	<0.001	0.26	<0.001
	f-DWI and DCE-MRI	0.81	<0.001	0.80	<0.001
<b>Internal pattern</b>	c-DWI and DCE-MRI	0.15	<0.001	0.23	<0.001
	f-DWI and DCE-MRI	0.68	<0.001	0.72	<0.001

c-DWI, conventional diffusion-weighted imaging; f-DWI, focus diffusion-weighted imaging; DCE-MRI, dynamic contrast-enhanced magnetic resonance imaging.

**Table 5.** Determining the consistency of DWI methods with DCE-MRI in terms of tumor morphology according to lesion size

<b>Tumor size grouping</b>													
Group	Count (Percentage)	Reader 1 Kappa values of shapes	P	Reader 2 Kappa values of shapes	P	Reader 1 Kappa values of margins	P	Reader 2 Kappa values of margins	P	Reader 1 Kappa values of internal patterns	P	Reader 2 Kappa values of internal patterns	P
Group 1 (<15mm)	36 (22%)												
Group 2 (16–25 mm)	56 (35%)												
Group 3 (>25 mm)	68 (43%)												
Group 1 (DCE-MRI with c-DWI)		0.061	0.52	0.227	<0.001	0.134	0.03	0.116	0.37	0.091	0.01	0.120	0.051
Group 2 (DCE-MRI with c-DWI)		0.203	0.02	0.373	<0.001	0.167	0.02	0.216	0.01	0.120	0.03	0.152	0.02
Group 3 (DCE-MRI with c-DWI)		0.227	0.03	0.408	<0.001	0.203	0.04	0.253	0.01	0.266	0.01	0.383	<0.001
Group 1 (DCE-MRI with f-DWI)		0.769	<0.001	0.719	<0.001	0.771	<0.001	0.712	<0.001	0.616	<0.001	0.642	<0.001
Group 2 (DCE-MRI with f-DWI)		0.819	<0.001	0.729	<0.001	0.700	<0.001	0.768	<0.001	0.758	<0.001	0.772	<0.001
Group 3 (DCE-MRI with f-DWI)		0.934	<0.001	0.935	<0.001	0.899	<0.001	0.861	<0.001	0.552	<0.001	0.636	<0.001

c-DWI, conventional diffusion-weighted imaging; f-DWI, focus diffusion-weighted imaging; DCE-MRI, dynamic contrast-enhanced magnetic resonance imaging.

**Table 6.** Interobserver agreement for assessment of tumor morphology

	Reader 1	Reader 2
<b>Shape</b>		
c-DWI	0.75	<0.001
f-DWI	0.63	<0.001
DCE-MRI	0.65	<0.001
<b>Margin</b>		
c-DWI	0.89	<0.001
f-DWI	0.87	<0.001
DCE-MRI	0.89	<0.001
<b>Internal</b>		
c-DWI	0.79	<0.001
<b>Pattern</b>		
f-DWI	0.71	<0.001
DCE-MRI	0.70	<0.001

c-DWI, conventional diffusion-weighted imaging; f-DWI, focus diffusion-weighted imaging; DCE-MRI, dynamic contrast-enhanced magnetic resonance imaging.

caused a higher rate of disagreement among readers and therefore lower intraobserver agreement. Based on these results, f-DWI can be considered a potential competitor to DCE-MRI in evaluating the morphological features and extent of breast masses, and the use of HR DWI together with c-DWI could increase diagnostic accuracy, especially in patients who cannot undergo contrast-enhanced imaging.

Another key result of our study, consistent with findings in the literature, is the determination of the ADC values obtained on f-DWIs as statistically lower than the ADC values obtained on c-DWIs.<sup>28,31,32</sup> Although this effect has been suggested to be secondary to a reduced partial volume effect of normal fibroglandular tissue and residual fat in HR images, the exact mechanism has not yet been fully clarified.<sup>2,11</sup> One of the reasons for the emergence of this difference with f-DWIs is that tumor heterogeneity and tumor in-

ternal pattern can be defined more clearly, and thus, the area of the tumor that exhibits the most prominent diffusion restriction can be accurately determined. A more accurate determination of ADC values may provide important benefits for tumor prognosis and an evaluation of response to treatment. For example, Wilmes et al.<sup>2</sup> compared changes in ADC values measured by HR-DWI and c-DWIs, revealing that lower ADC values obtained with HR-DWI were better correlated with regression in tumor size. Consistent with these findings, we believe that the more accurate ADC values obtained with HR-DWI will enable a more accurate assessment of tumor prognosis or response to treatment.

To our knowledge, this is the largest study population comparing c-DWI, HR-DWI, and DCE-MRI in determining the morphological characteristics of breast cancers. However, certain limitations should be considered.

First, due to the evaluation of only the morphological features of malignant tumors, the diagnostic capability of f-DWI in the differentiation of benign and malignant tumors could not be evaluated. Second, image quality analysis was based on the simultaneous evaluation of all the c-DWI, f-DWI, and DCE series side by side. This may have led to the emergence of biases that better quality images are obtained with f-DW and/or DCE-MR images. Therefore, it would be more appropriate to evaluate all three methods separately in future studies. Third, it may not be possible to determine the morphological features of all multifocal and multicentric lesions due to the examination of a limited area with f-DWI. For this reason, attempts should be made to define the most suspicious lesions more clearly using f-DWIs, especially in conjunction with c-DWIs. Finally, f-DWIs have a longer imaging time than c-DWIs.

In conclusion, our findings revealed the favorable utility of f-DWI in the detailed evaluation of the morphological features of primary breast cancer as a method that is not inferior to DCE-MRI and is superior to c-DWI. Especially in cases where dynamic contrast sequences cannot be obtained, it is possible to characterize suspicious lesions detected in conventional imaging more clearly and in detail with f-DWIs, which provide high-quality images due to greater sharpness, perceived SNR and lower distortion. This may enable more accurate diagnoses to be made.

### Conflict of interest disclosure

The authors declare that they have no conflicts of interest.

### References

- Partridge SC, Gibbs JE, Lu Y, et al. MRI measurements of breast tumor volume predict response to neoadjuvant chemotherapy and recurrence-free survival. *AJR Am J Roentgenol*. 2005;184(6):1774-1781. [\[Crossref\]](#)
- Wilmes LJ, McLaughlin RL, Newitt DC, et al. High-resolution diffusion-weighted imaging for monitoring breast cancer treatment response. *Acad Radiol*. 2013;20(5):581-589. [\[CrossRef\]](#)
- Orel SG. High-resolution MR imaging for the detection, diagnosis, and staging of breast cancer. *Radiographics*. 1998;18(4):903-912. [\[CrossRef\]](#)
- Kuhl CK, Schild HH, Morakkabati N. Dynamic bilateral contrast-enhanced MR imaging of the breast: trade-off between spatial and temporal resolution. *Radiology*. 2005;236(3):789-800. [\[CrossRef\]](#)
- Woodhams R, Ramadan S, Stanwell P, et al. Diffusion-weighted imaging of the breast: principles and clinical applications. *Radiographics*. 2011;31(4):1059-1084. [\[CrossRef\]](#)
- Ei Khouli RH, Jacobs MA, Mezban SD, et al. Diffusion-weighted imaging improves the diagnostic accuracy of conventional 3.0-T breast MR imaging. *Radiology*. 2010;256(1):64-73. [\[CrossRef\]](#)
- Mansfield P. Multi-planar image-formation using NMR spin echoes. *J Phys C: Solid State Phys*. 1977;10(3):55-58. [\[CrossRef\]](#)
- Turner R, Le Bihan D. Single-shot diffusion imaging at 2.0 Tesla. *J Magn Reson Imaging*. 1990;86(3):445-452. [\[CrossRef\]](#)
- Zaharchuk G, Saritas EU, Andre JB, et al. Reduced field-of-view diffusion imaging of the human spinal cord: comparison with conventional single-shot echo-planar imaging. *AJNR Am J Neuroradiol*. 2011;32(5):813-820. [\[CrossRef\]](#)
- Karampinos DC, Van AT, Olivero WC, Georgiadis JG, Sutton BP. High resolution reduced-FOV diffusion tensor imaging of the human pons with multi-shot variable density spiral at 3T. *Annu Int Conf IEEE Eng Med Biol Soc*. 2008;2008:5761-5764. [\[CrossRef\]](#)
- Singer L, Wilmes LJ, Saritas EU, et al. High-resolution diffusion-weighted magnetic resonance imaging in patients with locally advanced breast cancer. *Acad Radiol*. 2012;19(5):526-534. [\[CrossRef\]](#)
- Saritas EU, Cunningham CH, Lee JH, Han ET, Nishimura DG. DWI of the spinal cord with reduced FOV single-shot EPI. *Magn Reson Med*. 2008;60(2):468-473.
- Finsterbusch J. High-resolution diffusion tensor imaging with inner field-of-view EPI. *J Magn Reson Imaging*. 2009;29(4):987-993. [\[CrossRef\]](#)
- Wilm BJ, Svensson J, Henning A, Pruessmann KP, Boesiger P, Kollias SS. Reduced field-of-view MRI using outer volume suppression for spinal cord diffusion imaging. *Magn Reson Med*. 2007;57(3):625-630. [\[CrossRef\]](#)
- Wheeler-Kingshott CA, Hickman SJ, Parker GJ, et al. Investigating cervical spinal cord structure using axial diffusion tensor imaging. *Neuroimage*. 2002;16(1):93-102. [\[CrossRef\]](#)
- Kang BJ, Lipson JA, Planey KR, et al. Rim sign in breast lesions on diffusion-weighted magnetic resonance imaging: diagnostic accuracy and clinical usefulness. *J Magn Reson Imaging*. 2015;41(3):616-623. [\[CrossRef\]](#)
- Kul S, Metin Y, Kul M, Metin N, Eyuboglu I, Ozdemir O. Assessment of breast mass morphology with diffusion-weighted MRI: Beyond apparent diffusion coefficient. *J Magn Reson Imaging*. 2018;48(6):1668-1677. [\[CrossRef\]](#)
- Barentsz MW, Taviani V, Chang JM, et al. Assessment of tumor morphology on diffusion-weighted (DWI) breast MRI: diagnostic value of reduced field of view DWI. *J Magn Reson Imaging*. 2015;42(6):1656-1665. [\[CrossRef\]](#)
- Radovic N, Ivanac G, Divjak E, Biondic I, Bulum A, Brkljacic B. Evaluation of breast cancer morphology using diffusion-weighted and dynamic contrast-enhanced MRI: intermethod and interobserver agreement. *J Magn Reson Imaging*. 2019;49(5):1381-1390. [\[CrossRef\]](#)
- Kishimoto AO, Kataoka M, Lima M, et al. The comparison of high-resolution diffusion weighted imaging (DWI) with high-resolution contrast-enhanced MRI in the evaluation of breast cancers. *Magn Reson Imaging*. 2020;71:161-169. [\[CrossRef\]](#)
- American College of Radiology. ACR BI-RADS magnetic resonance imaging. Reston, VA: American College of Radiology. Website: www.acr.org. Published 2013. Accessed June 20, 2016. [\[CrossRef\]](#)
- McHugh ML. Interrater reliability: the kappa statistic. *Biochem Med (Zagreb)*. 2012;22(3):276-282. [\[CrossRef\]](#)
- Koo TK, Li MY. A guideline of selecting and reporting intraclass correlation coefficients for reliability research. *J Chiropr Med*. 2016;15(2):155-163. Erratum in: *J Chiropr Med*. 2017;16(4):346. [\[CrossRef\]](#)
- Liu PF, Debatin JF, Caduff RF, Kacal G, Garzoli E, Krestin GP. Improved diagnostic accuracy in dynamic contrast enhanced MRI of the breast by combined quantitative and qualitative analysis. *Br J Radiol*. 1998;71(845):501-509. [\[CrossRef\]](#)
- Goto M, Ito H, Akazawa K, et al. Diagnosis of breast tumors by contrast-enhanced MR imaging: comparison between the diagnostic performance of dynamic enhancement patterns and morphologic features. *J Magn Reson Imaging*. 2007;25(1):104-112. [\[CrossRef\]](#)
- Park MJ, Cha ES, Kang BJ, Ihn YK, Baik JH. The role of diffusion-weighted imaging and the apparent diffusion coefficient (ADC) values for breast tumors. *Korean J Radiol*. 2007;8(5):390-396. [\[CrossRef\]](#)
- Yabuuchi H, Matsuo Y, Okafuji T, et al. Enhanced mass on contrast-enhanced breast MR imaging: lesion characterization using combination of dynamic contrast-enhanced and diffusion-weighted MR images. *J Magn Reson Imaging*. 2008;28(5):1157-1165. [\[CrossRef\]](#)
- Kishimoto AO, Kataoka M, Lima M, et al. Evaluation of malignant breast lesions using high-resolution readout-segmented diffusion-weighted echo-planar imaging: comparison with pathology. *Magn Reson Med Sci*. 2021;20(2):204-215. [\[CrossRef\]](#)
- Dong H, Li Y, Li H, Wang B, Hu B. Study of the reduced field-of-view diffusion-weighted imaging of the breast. *Clin Breast Cancer*. 2014;14(4):265-271. [\[CrossRef\]](#)



30. McKay JA, Church AL, Rubin N, et al. A comparison of methods for high-spatial-resolution diffusion-weighted imaging in breast MRI. *Radiology*. 2020;297(2):304-312. [\[CrossRef\]](#)
31. Wisner DJ, Rogers N, Deshpande VS, et al. High-resolution diffusion-weighted imaging for the separation of benign from malignant BI-RADS 4/5 lesions found on breast MRI at 3T. *J Magn Reson Imaging*. 2014;40(3):674-681. [\[CrossRef\]](#)
32. Yamaguchi K, Nakazono T, Egashira R, et al. Diagnostic performance of diffusion tensor imaging with readout-segmented echo-planar imaging for invasive breast cancer: correlation of ADC and FA with pathological prognostic markers. *Magn Reson Med Sci*. 2017;16(3):245-252. [\[CrossRef\]](#)